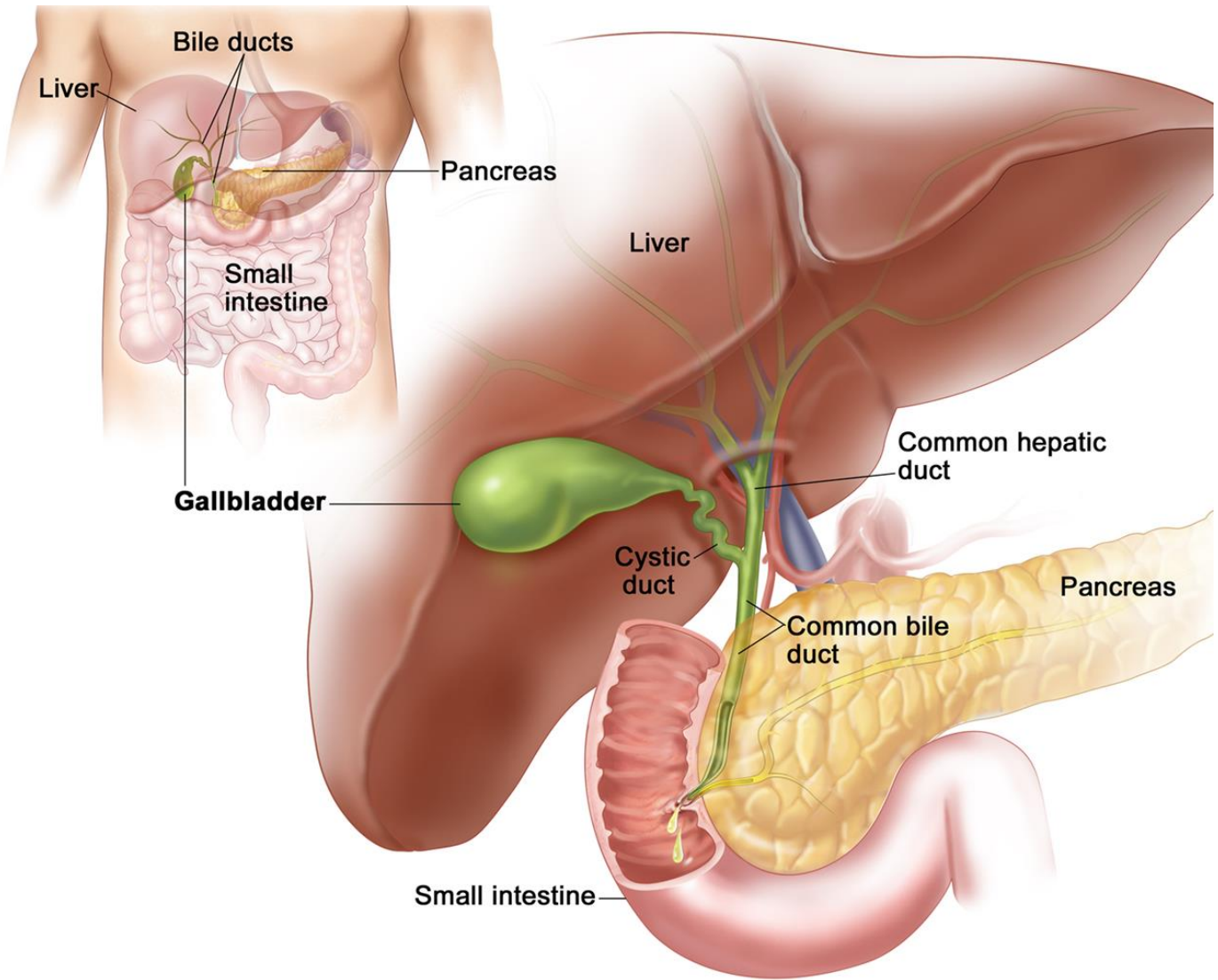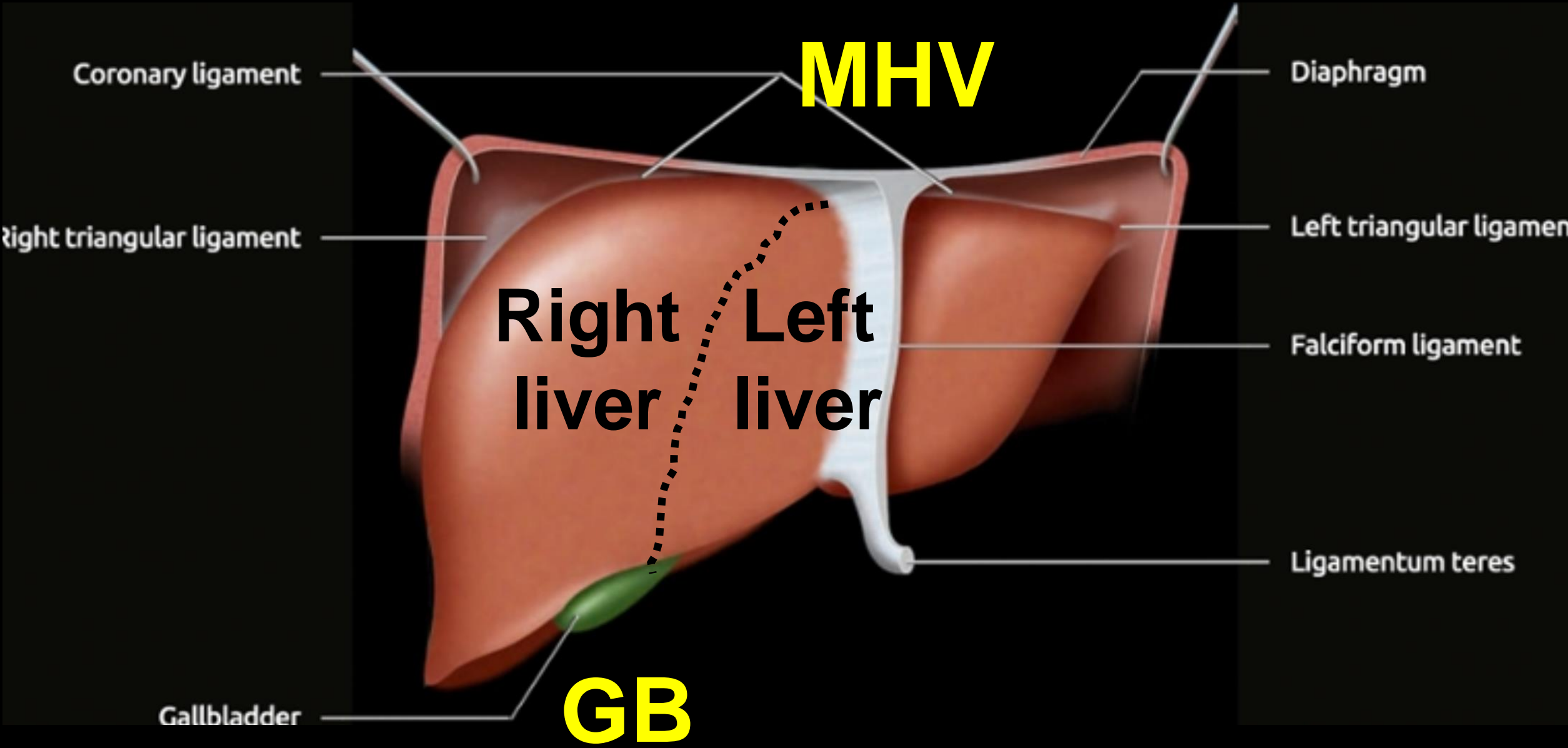


基礎 腹部超音波

中國醫藥大學附設醫院
急重症超音波訓練中心



MHV

**Right
liver**

**Left
liver**

GB

Coronary ligament

Diaphragm

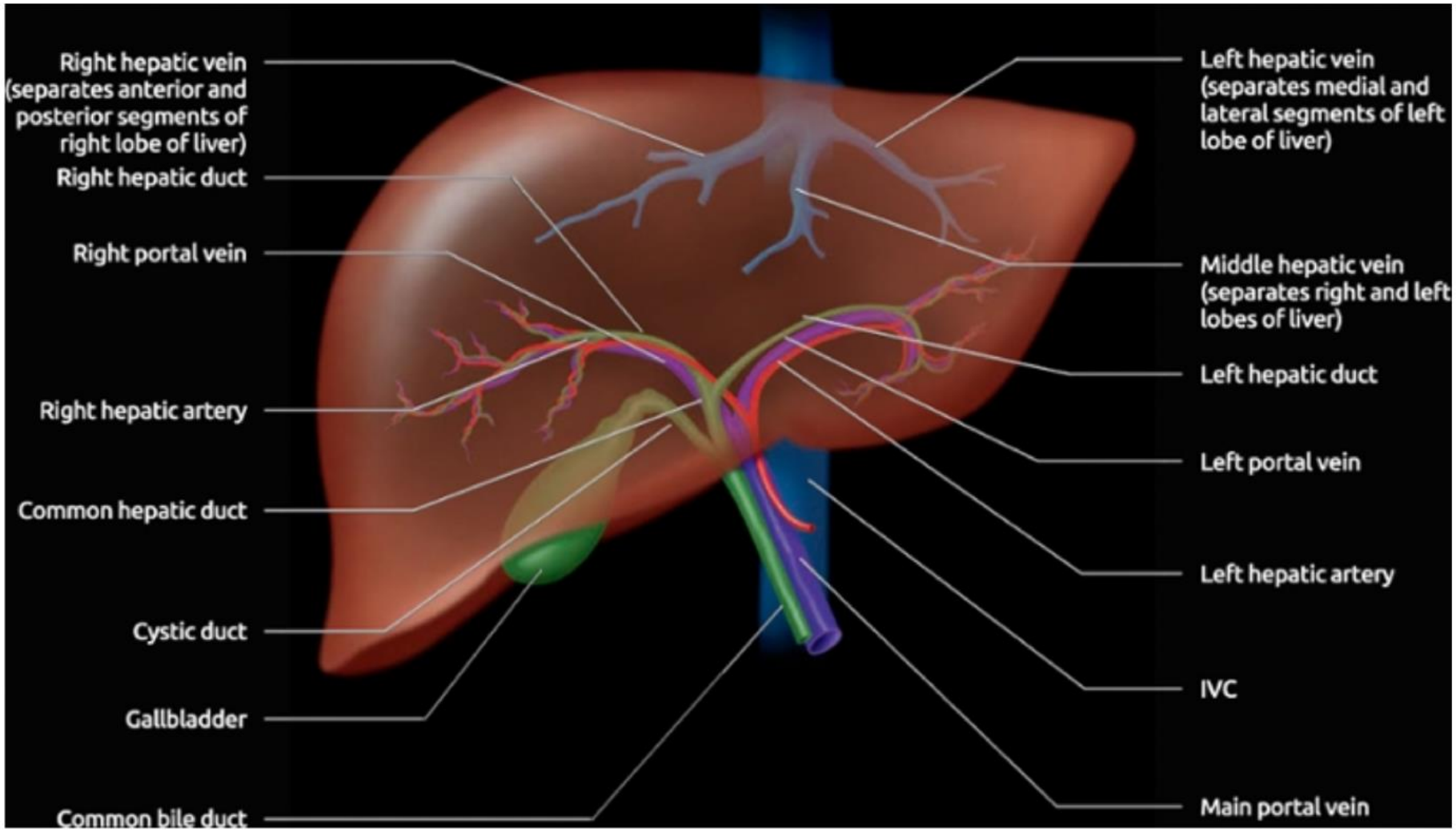
Right triangular ligament

Left triangular ligament

Falciform ligament

Gallbladder

Ligamentum teres



Right hepatic vein
(separates anterior and
posterior segments of
right lobe of liver)

Right hepatic duct

Right portal vein

Right hepatic artery

Common hepatic duct

Cystic duct

Gallbladder

Common bile duct

Left hepatic vein
(separates medial and
lateral segments of left
lobe of liver)

Middle hepatic vein
(separates right and left
lobes of liver)

Left hepatic duct

Left portal vein

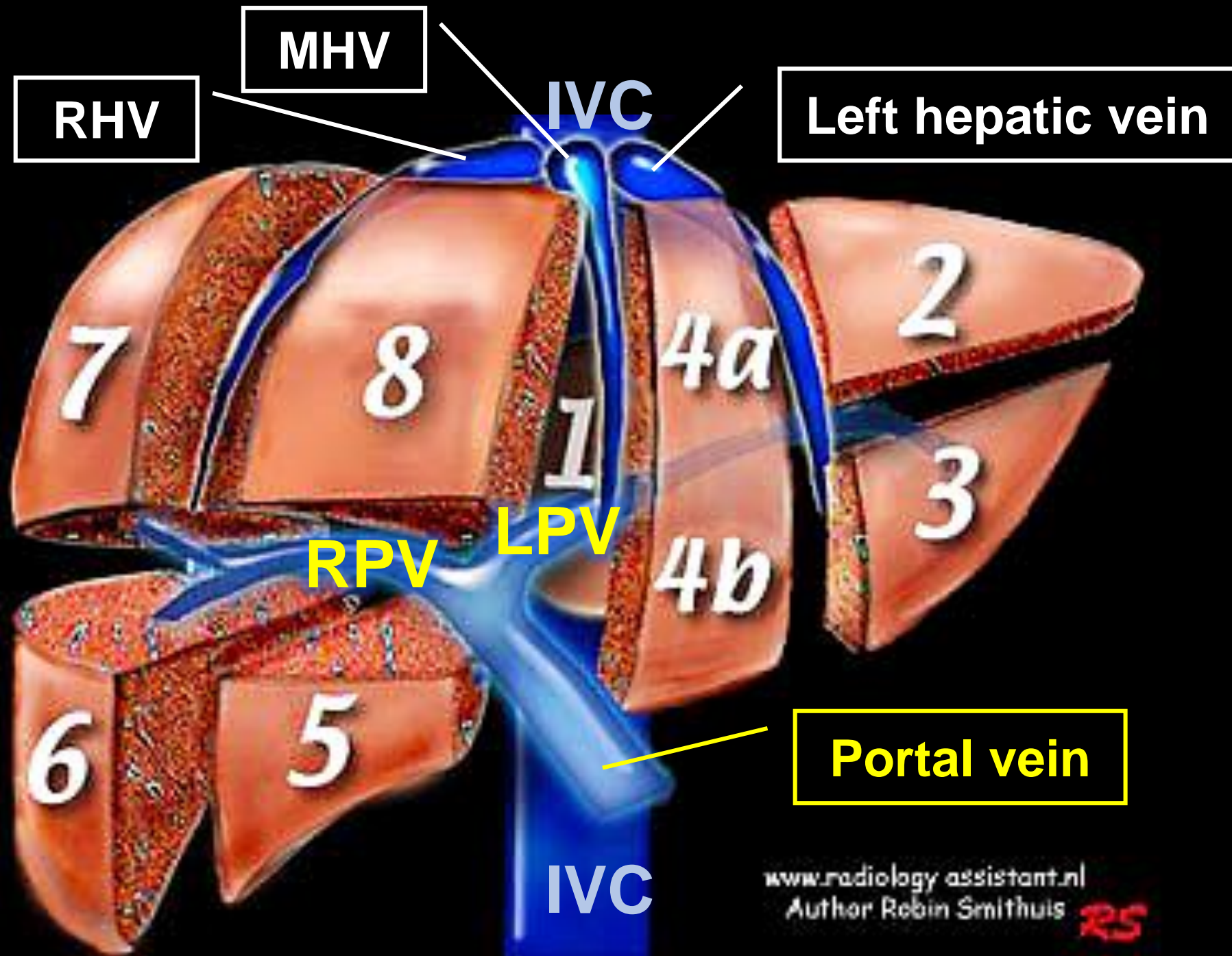
Left hepatic artery

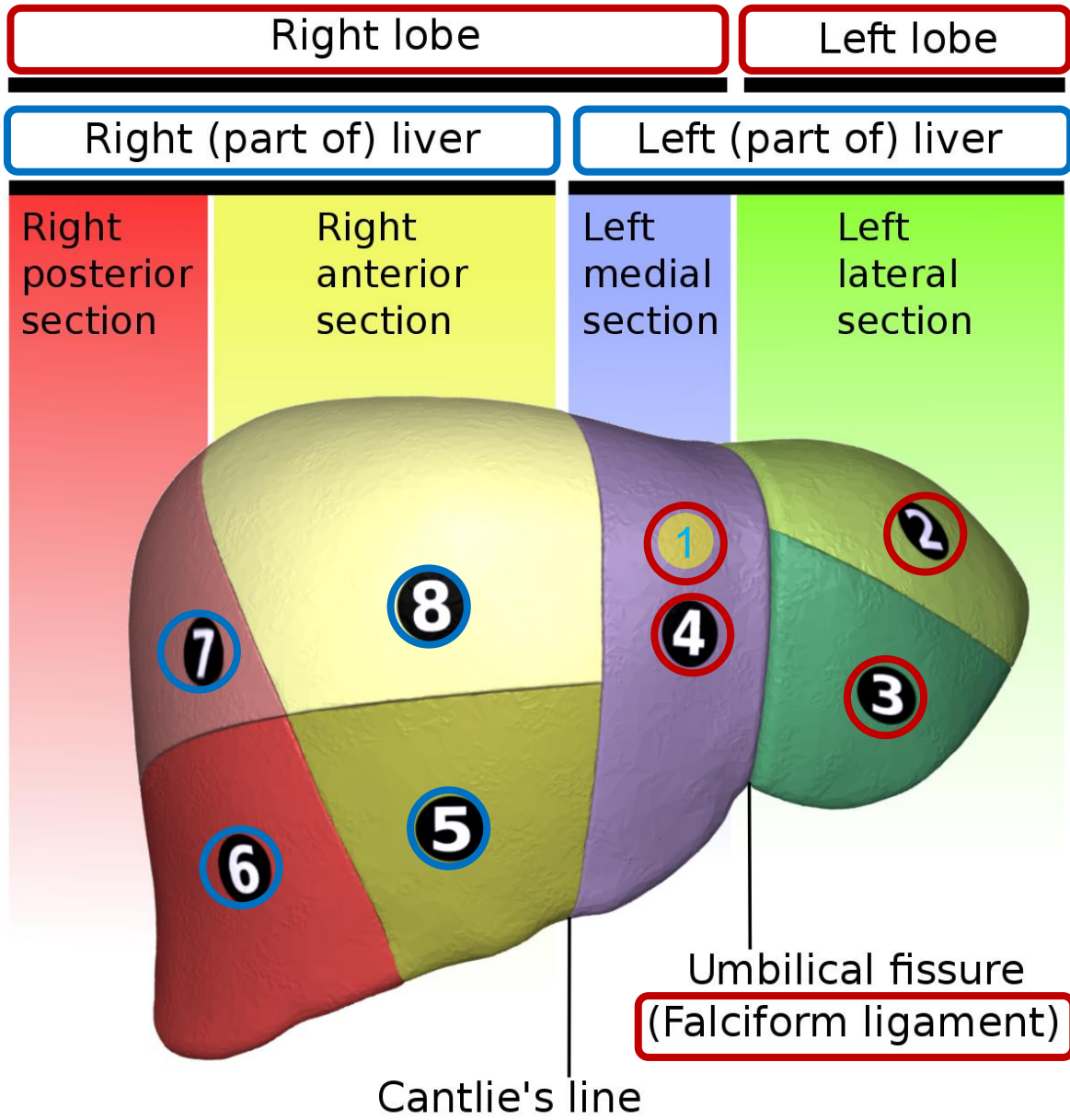
IVC

Main portal vein

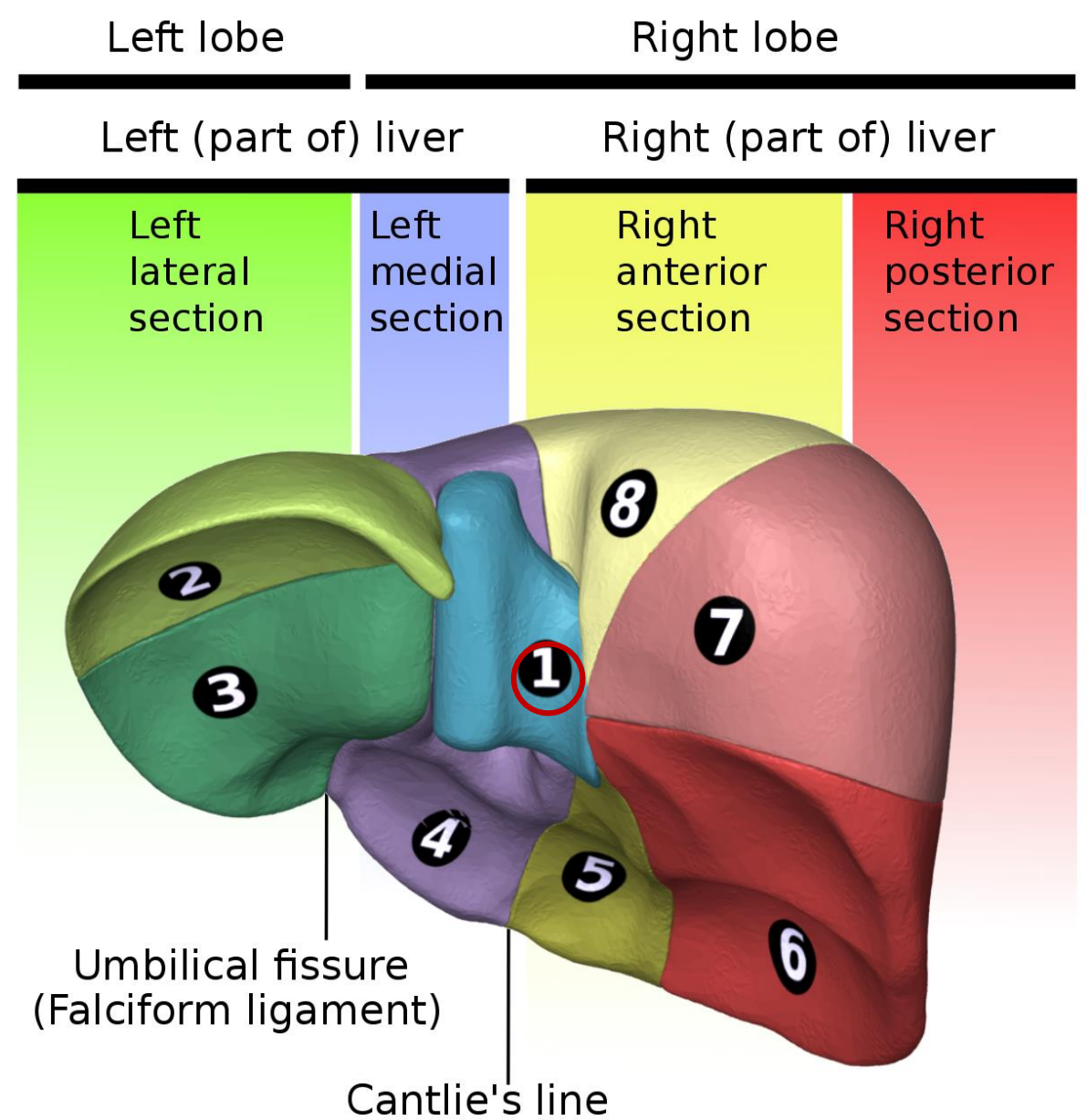
縱切肝臟

橫切肝臟



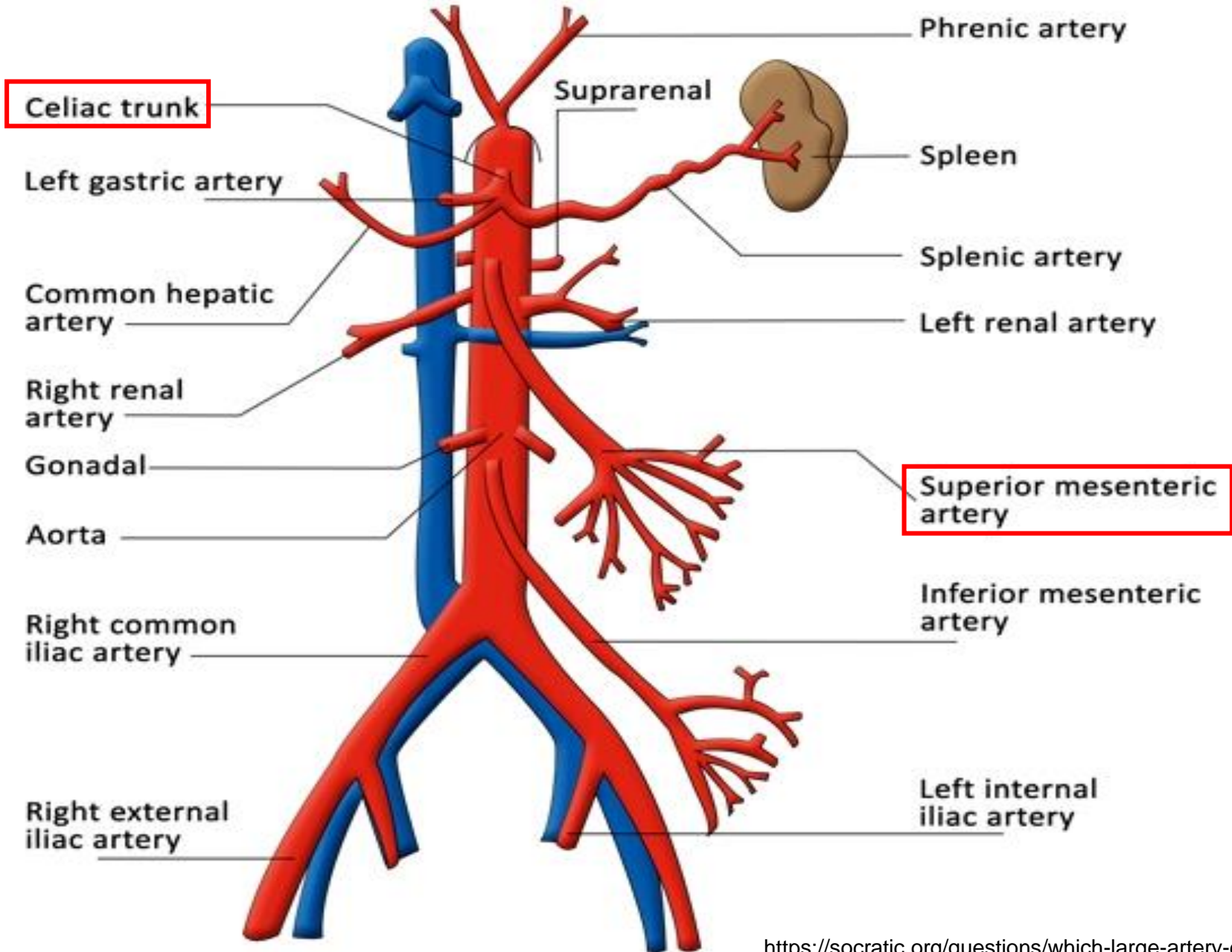


Anterior view



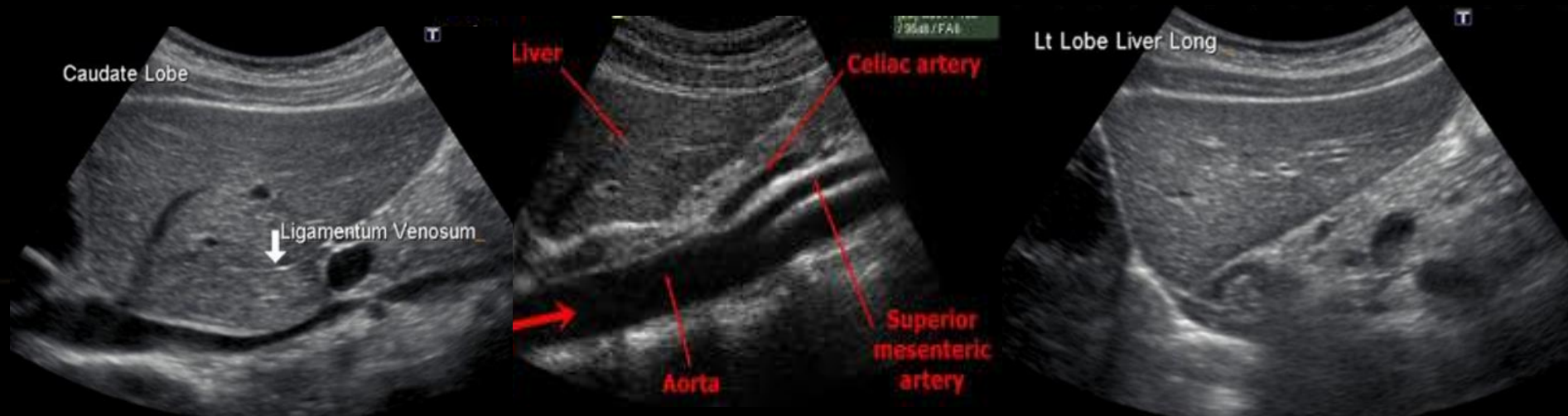
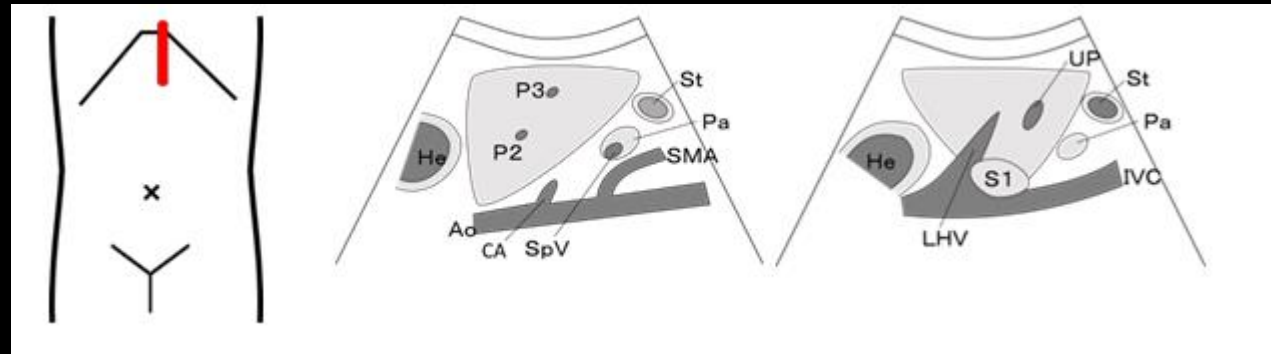
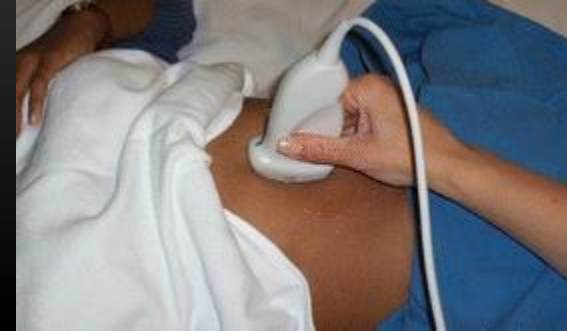Posterior view

IVC Aorta



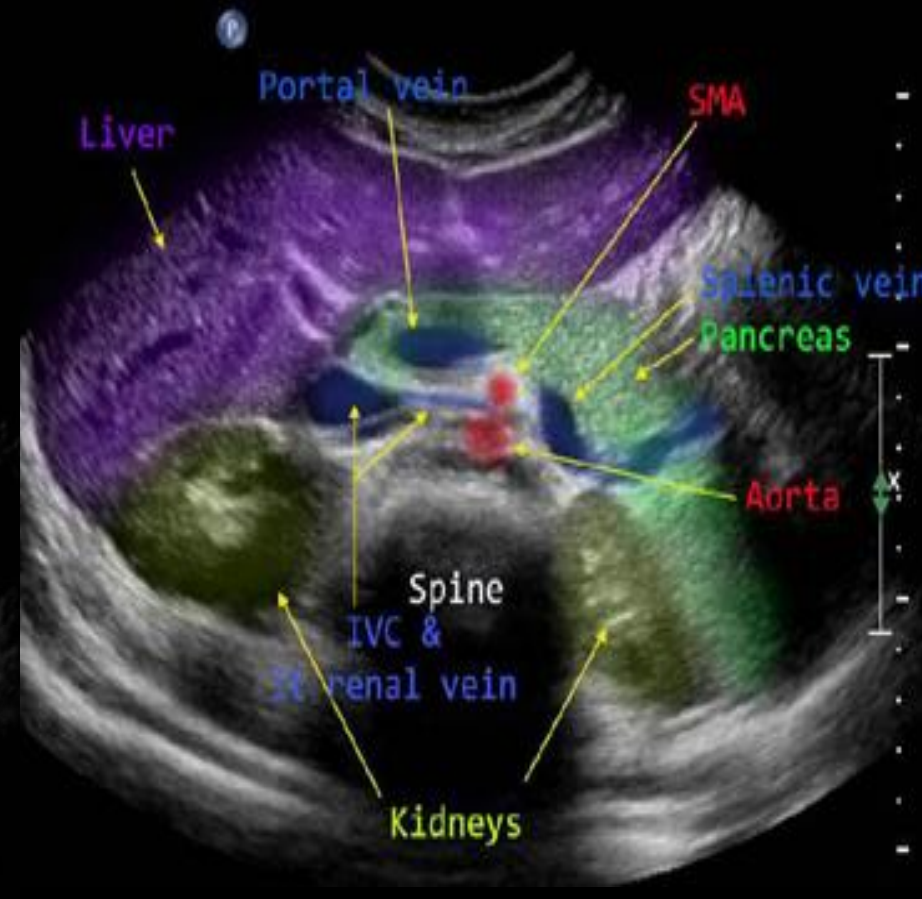
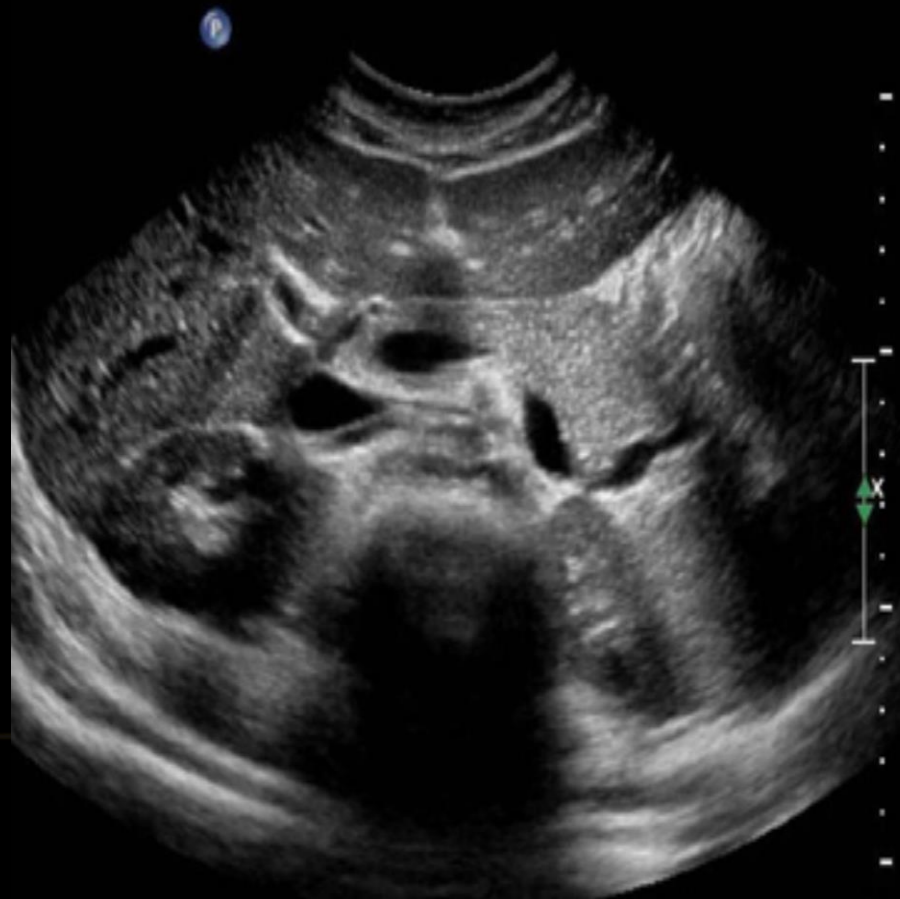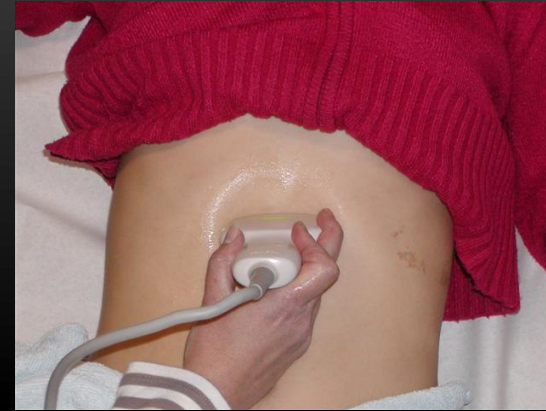Left Lobe Of Liver

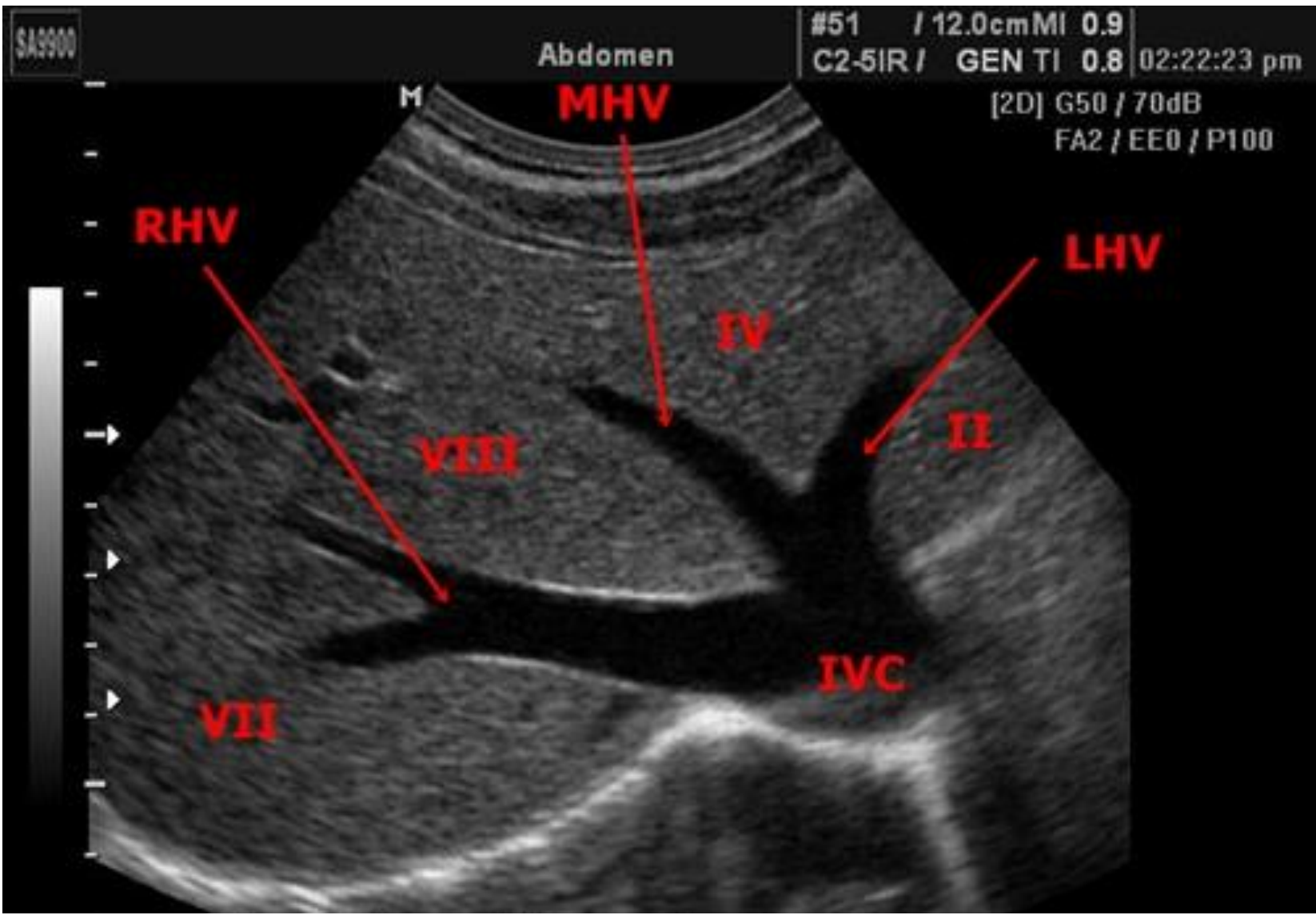
Sagittal View of the Left Lobe

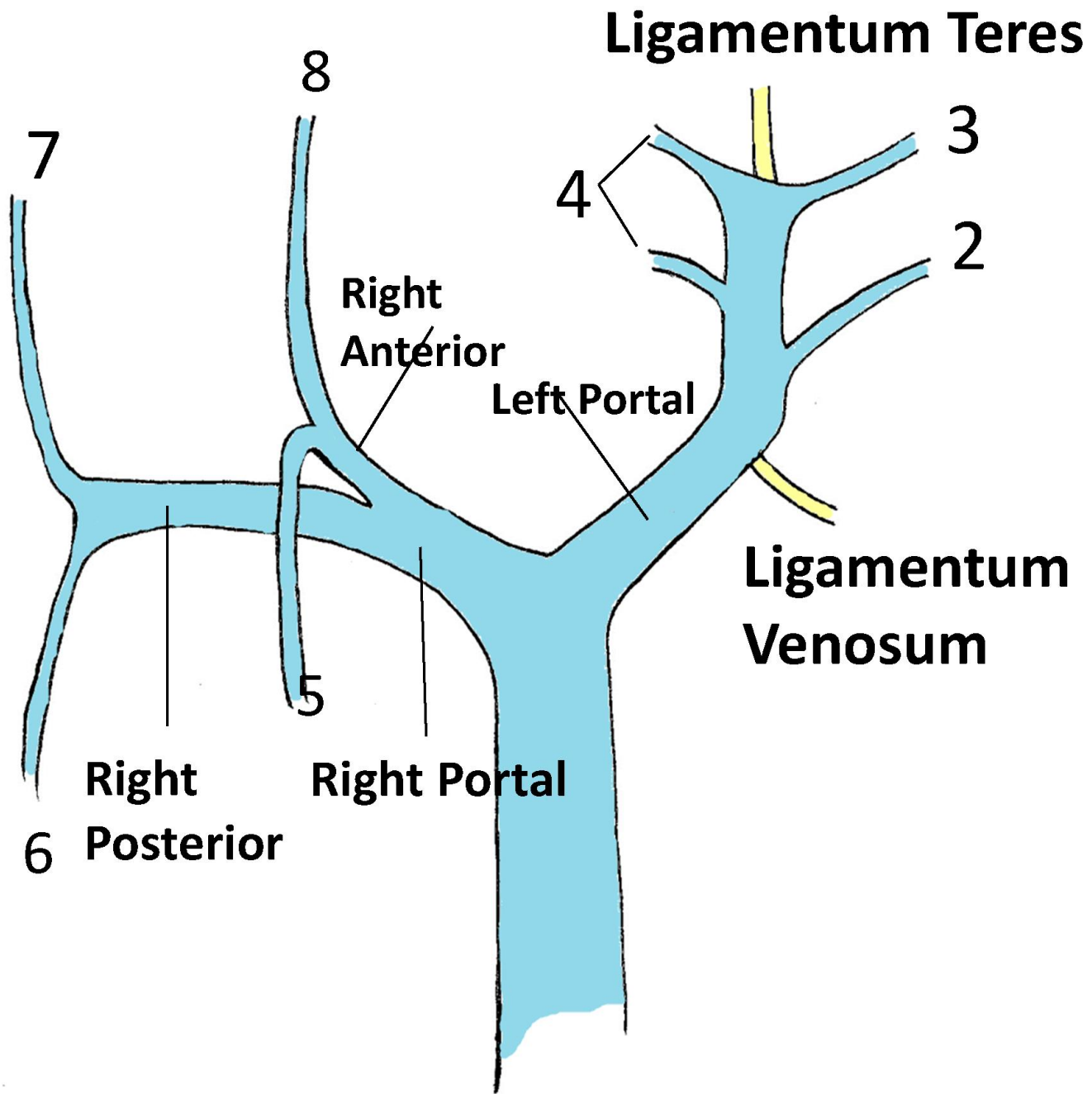


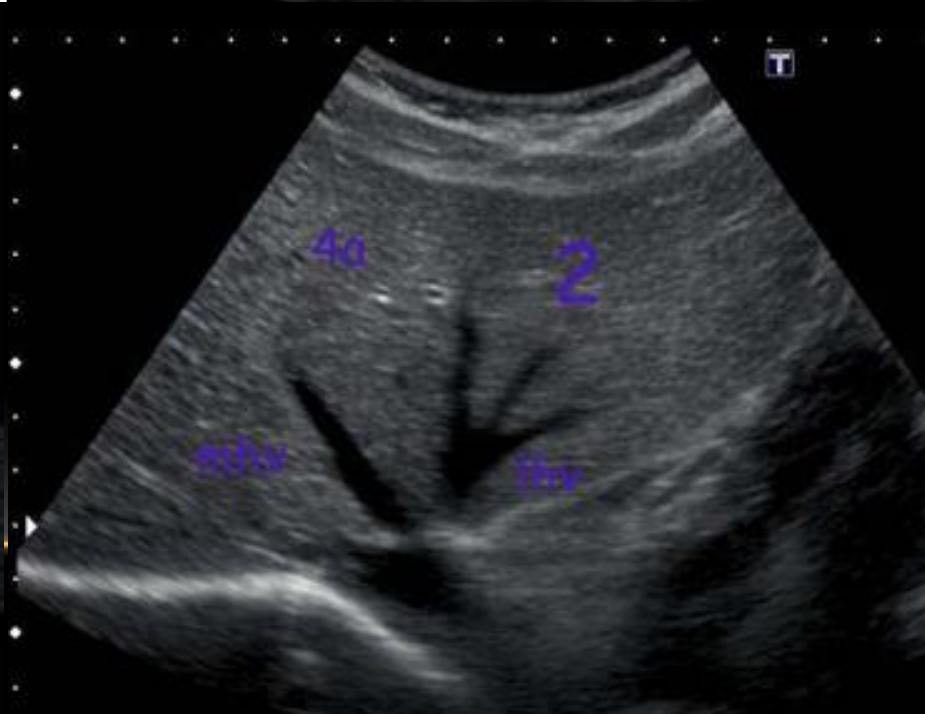
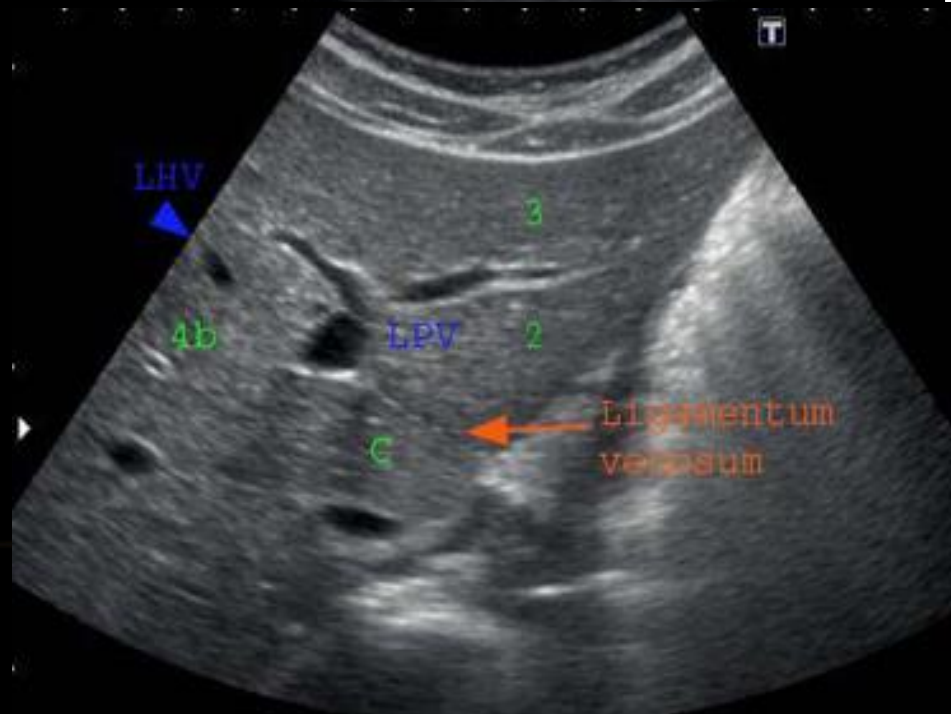
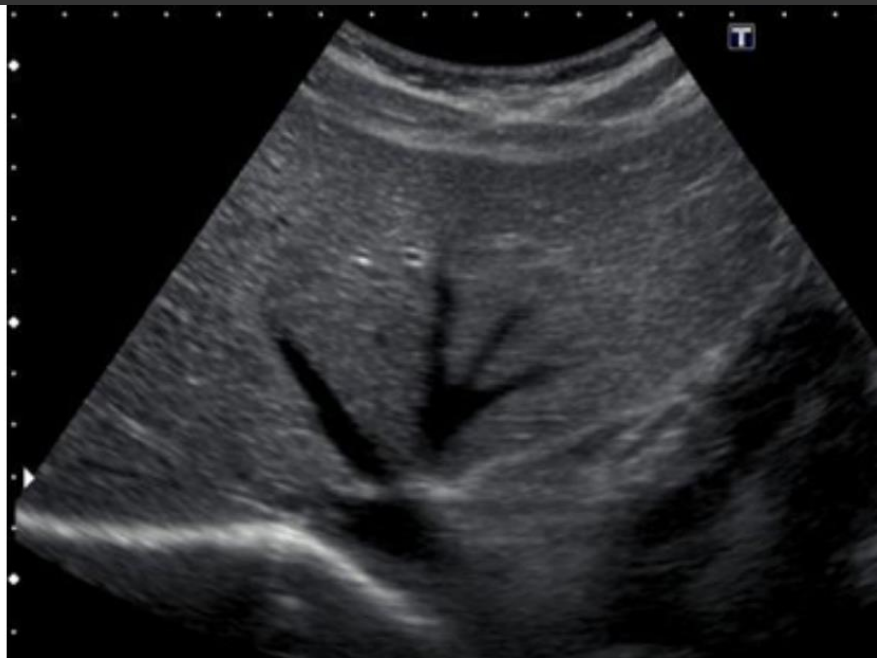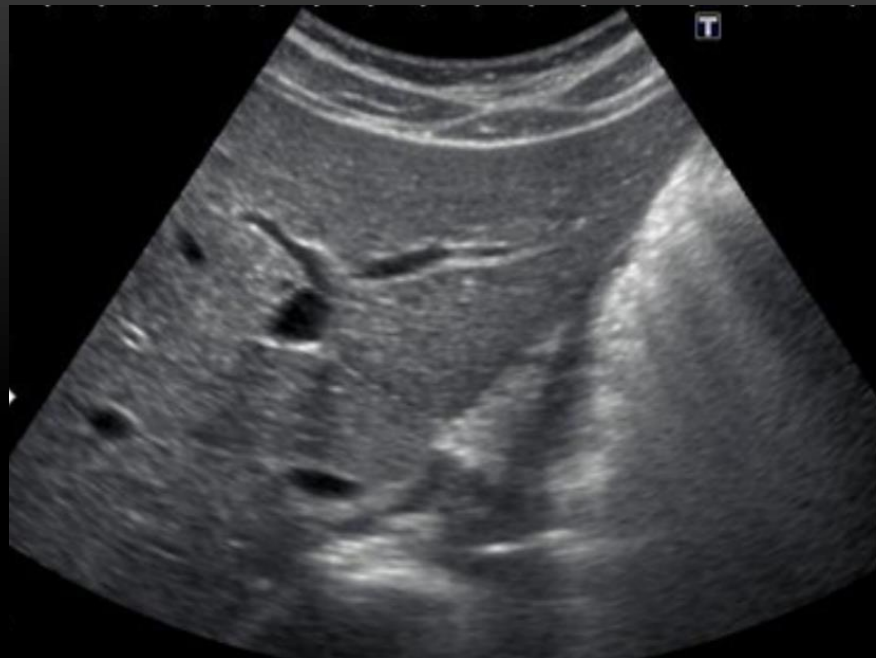Left Lobe Of Liver

Transverse View of the Left Lobe



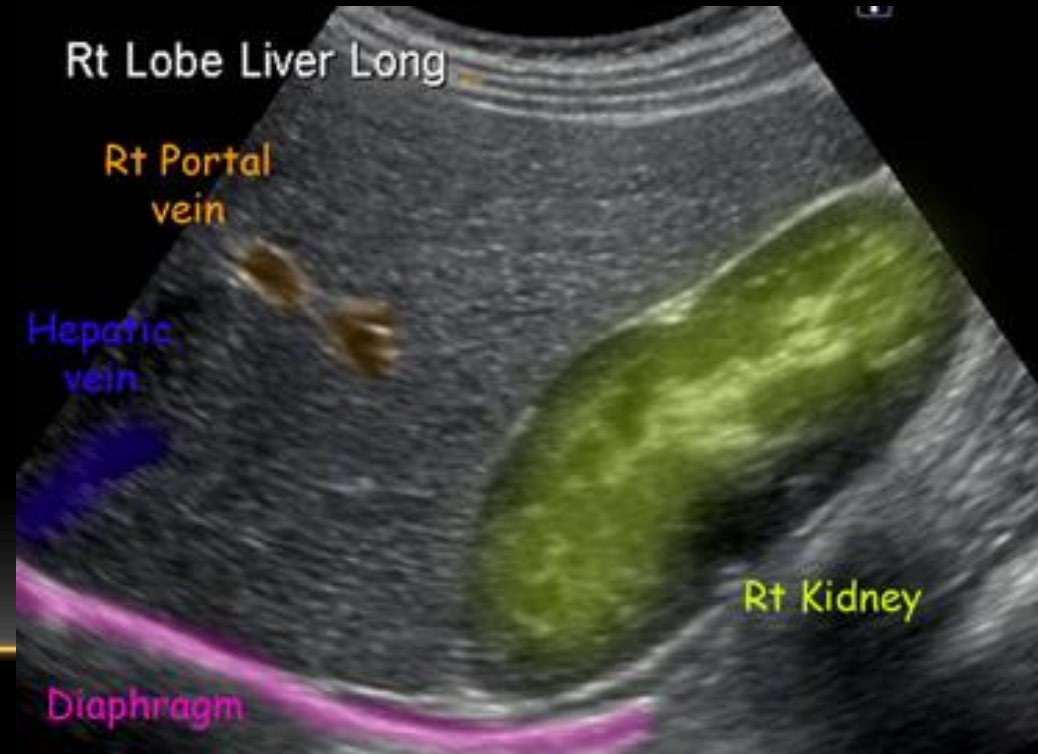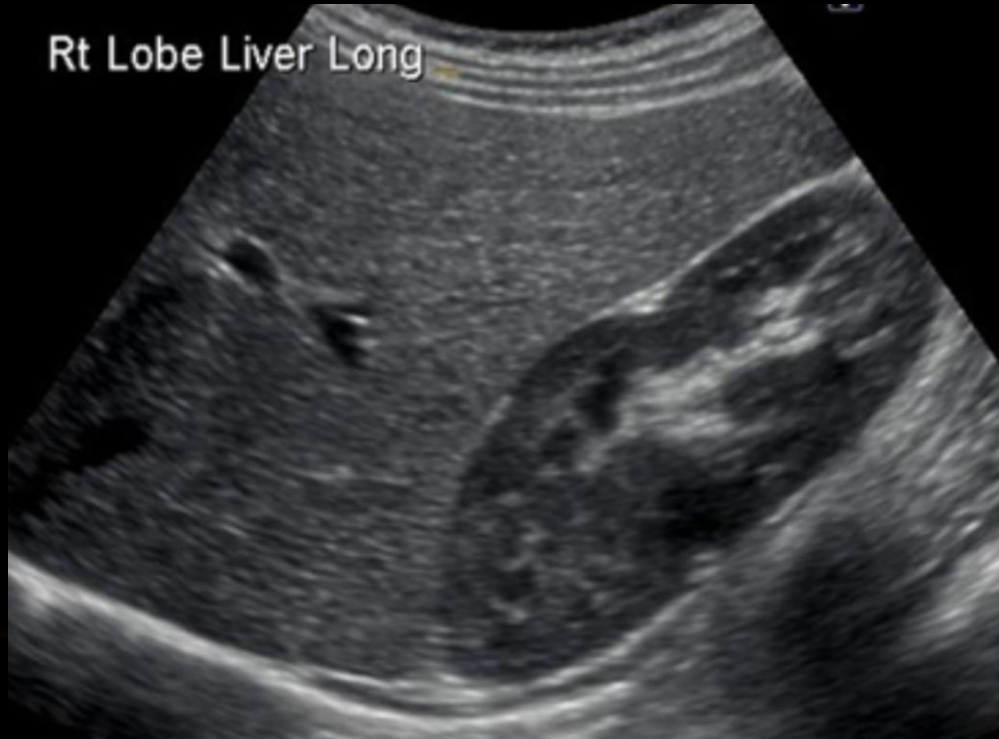

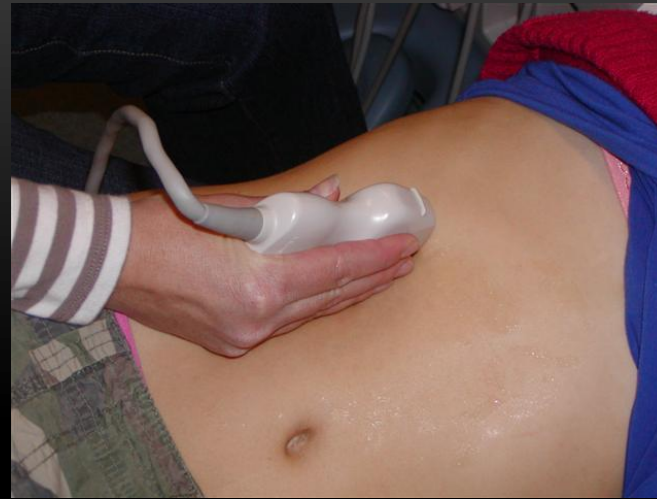
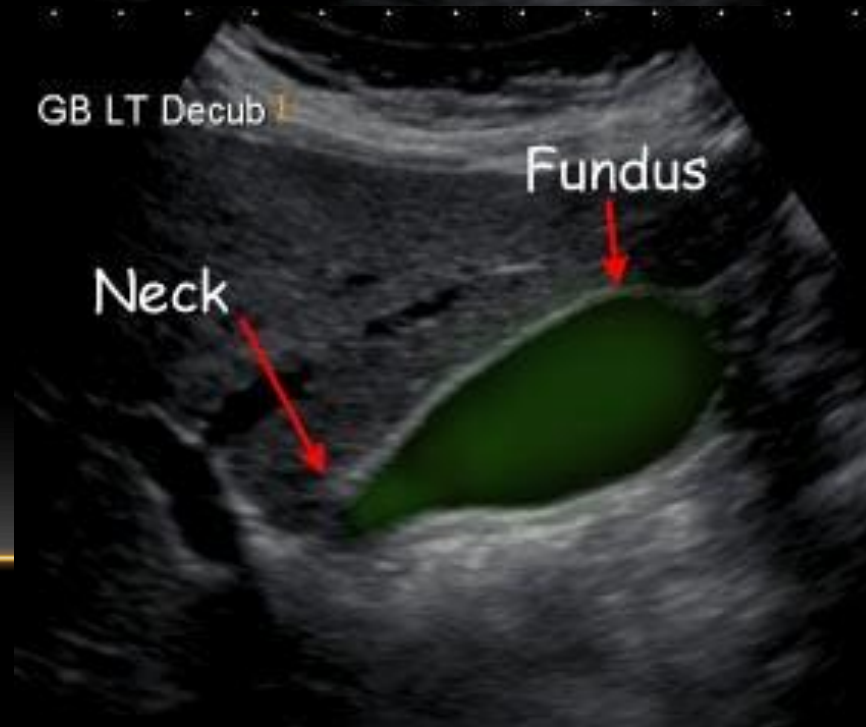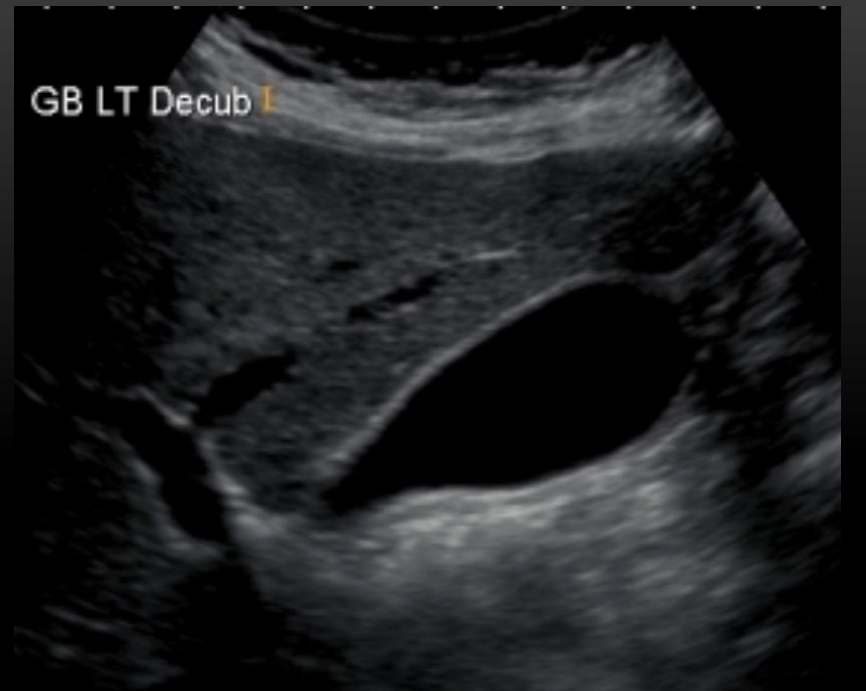
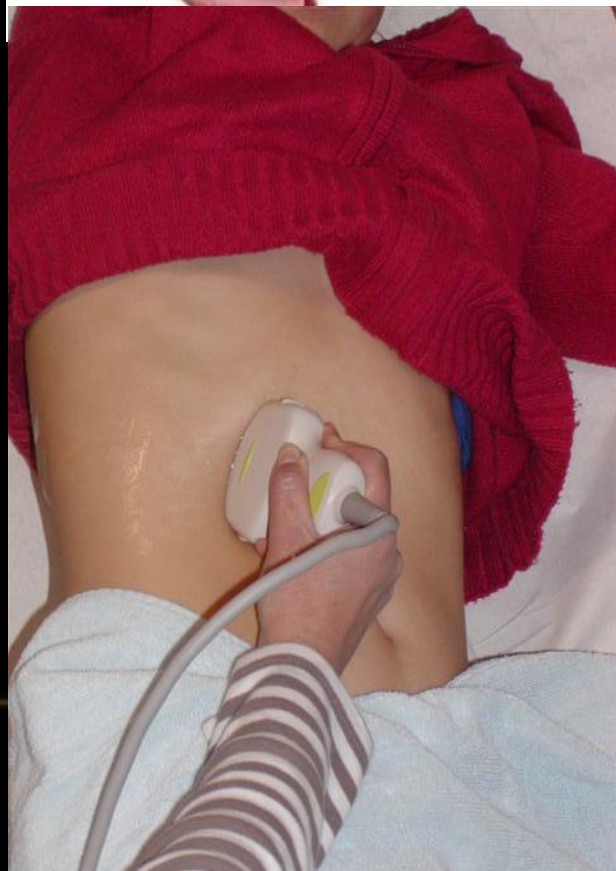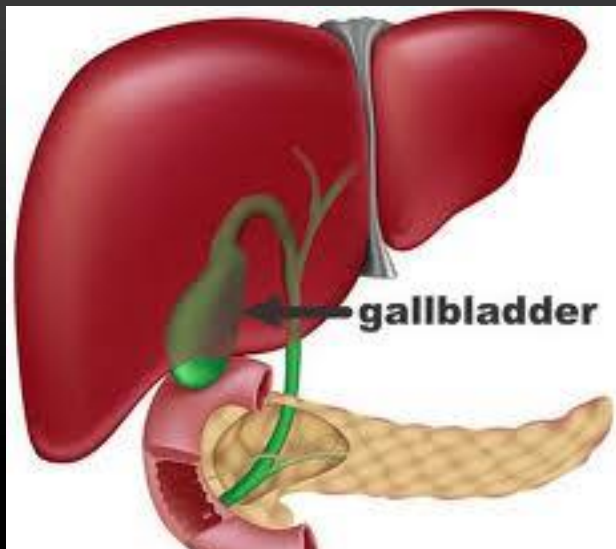




Rt Lobe Liver

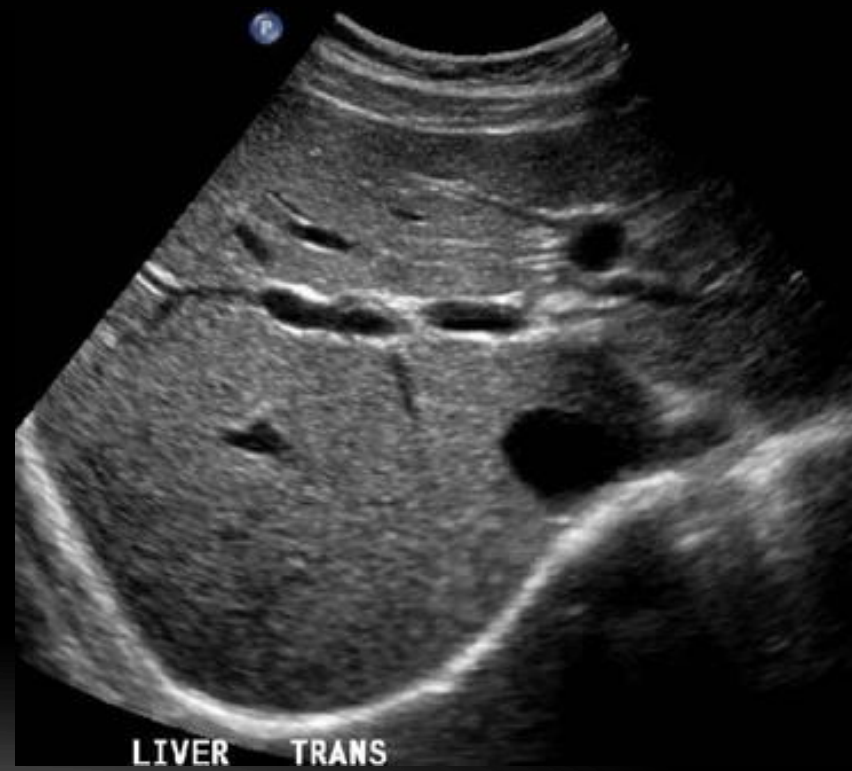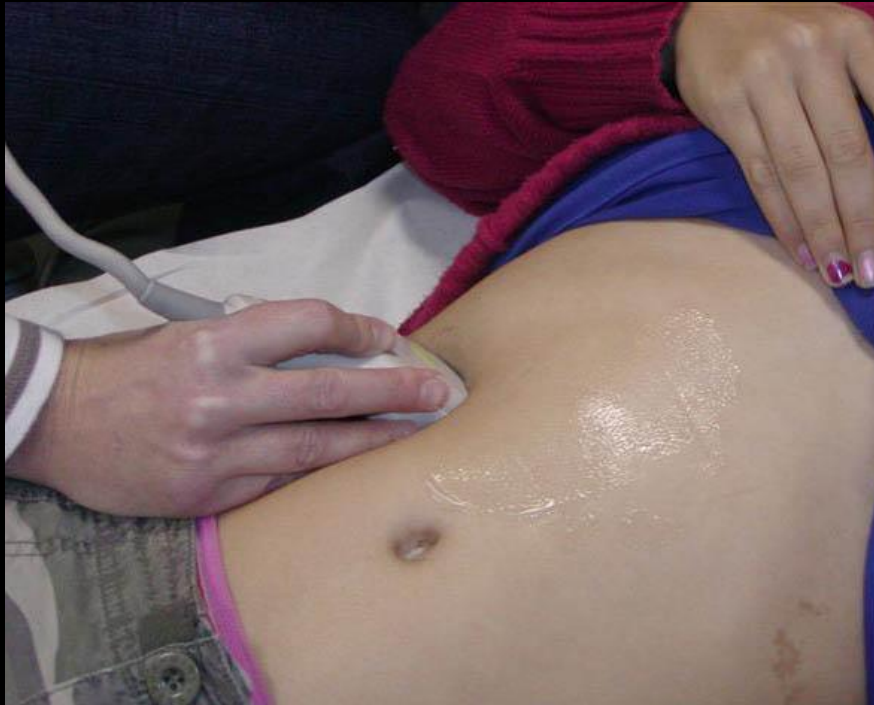Parasagittal Scan Plane

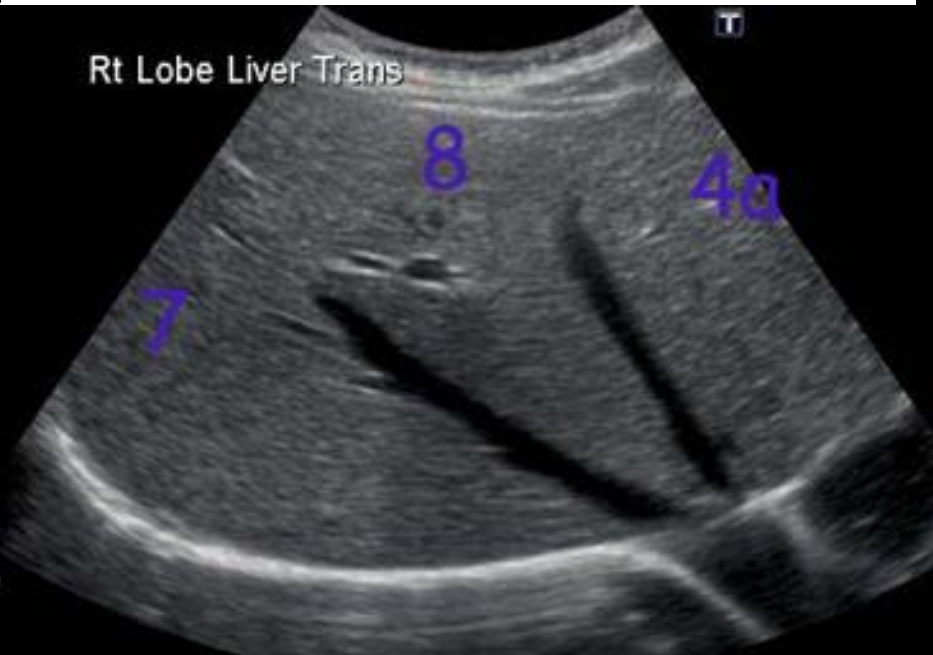
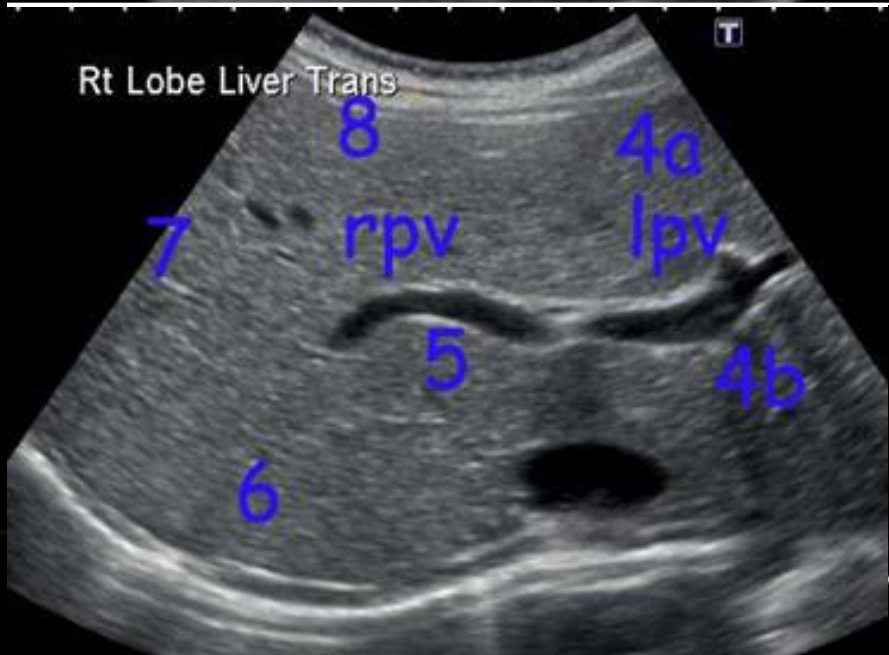
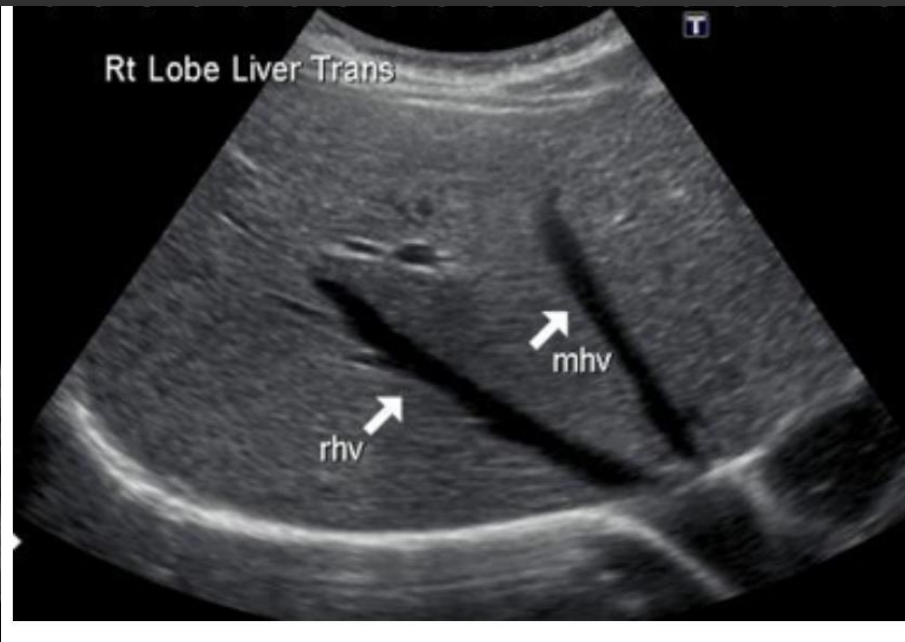
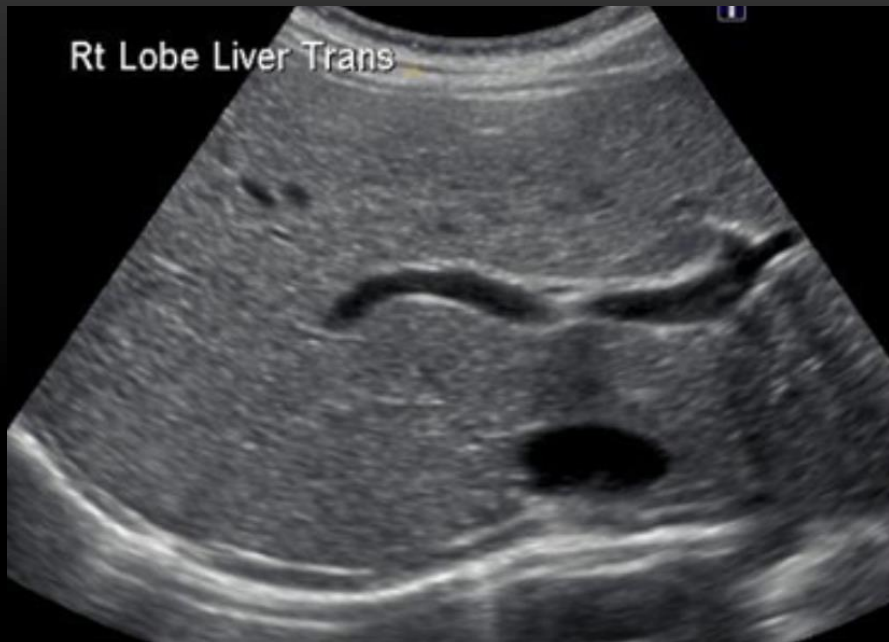
Rt Lobe Liver

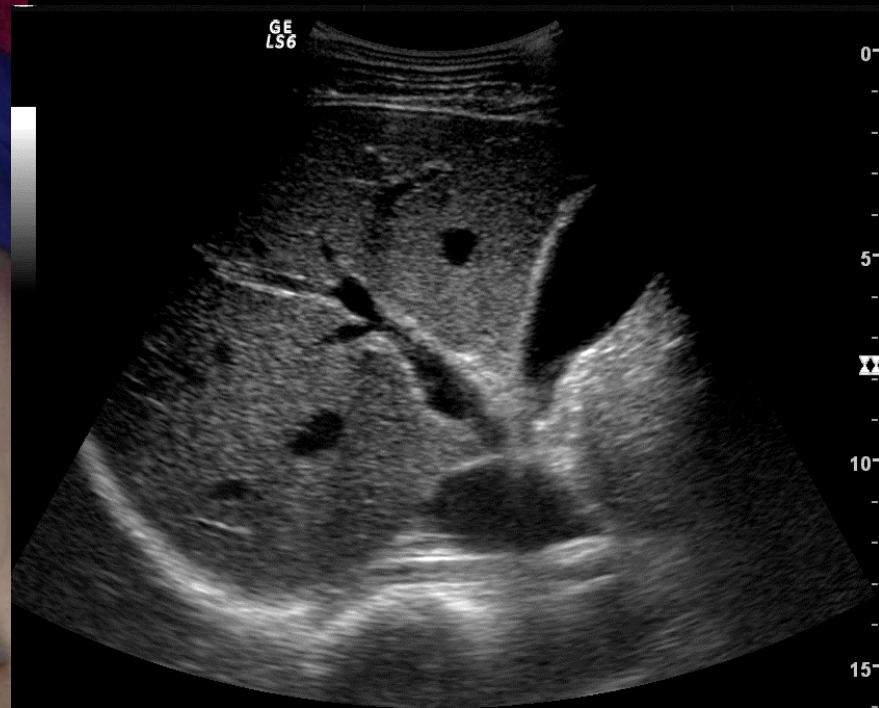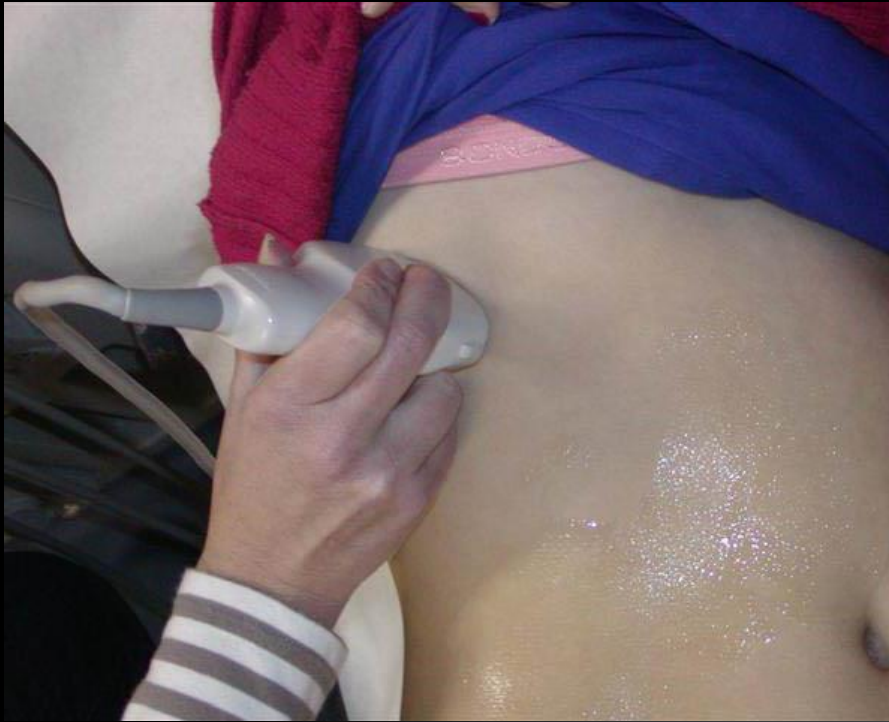Subcostal Scan Plane

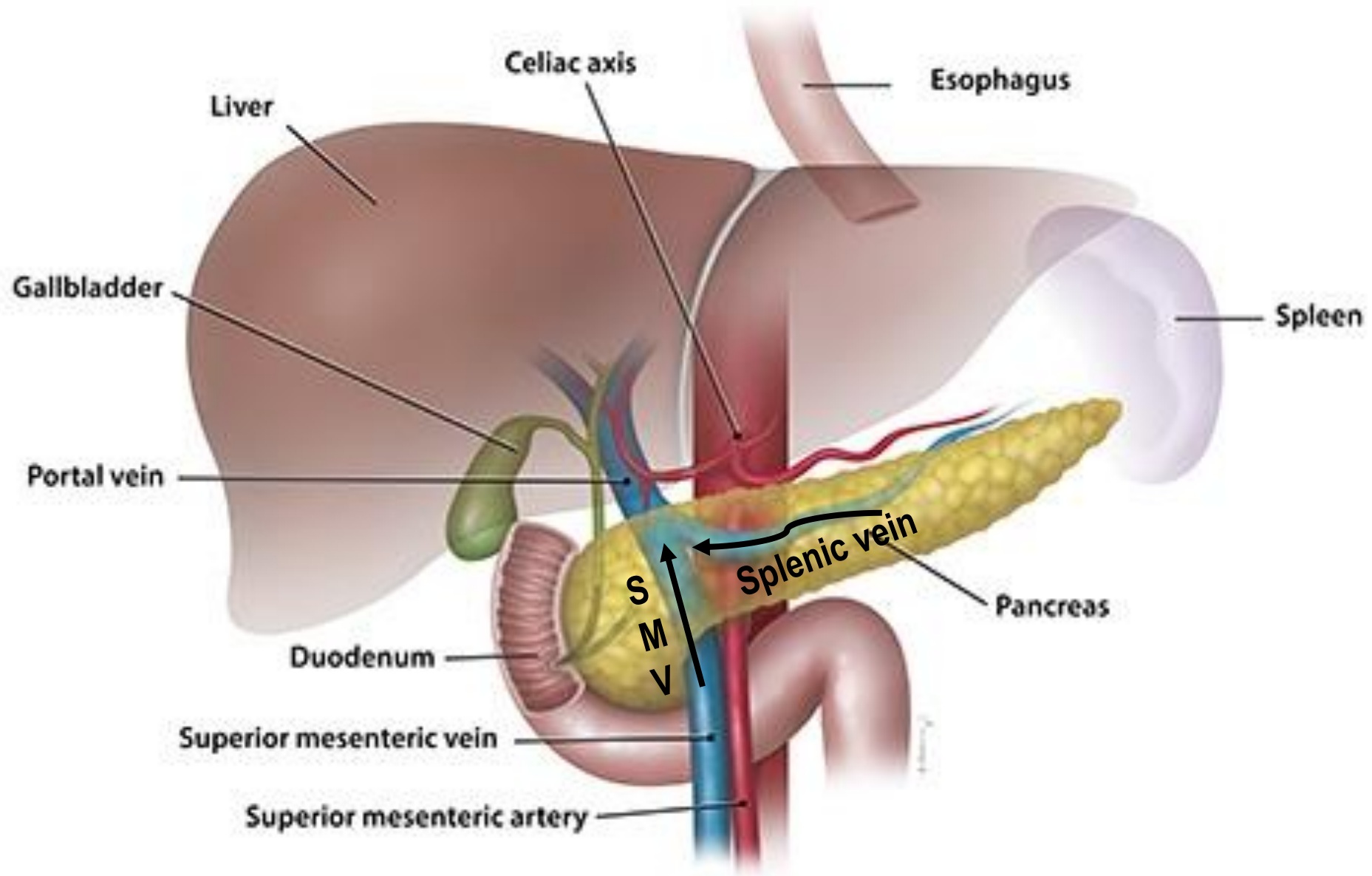




Rt Lobe Liver

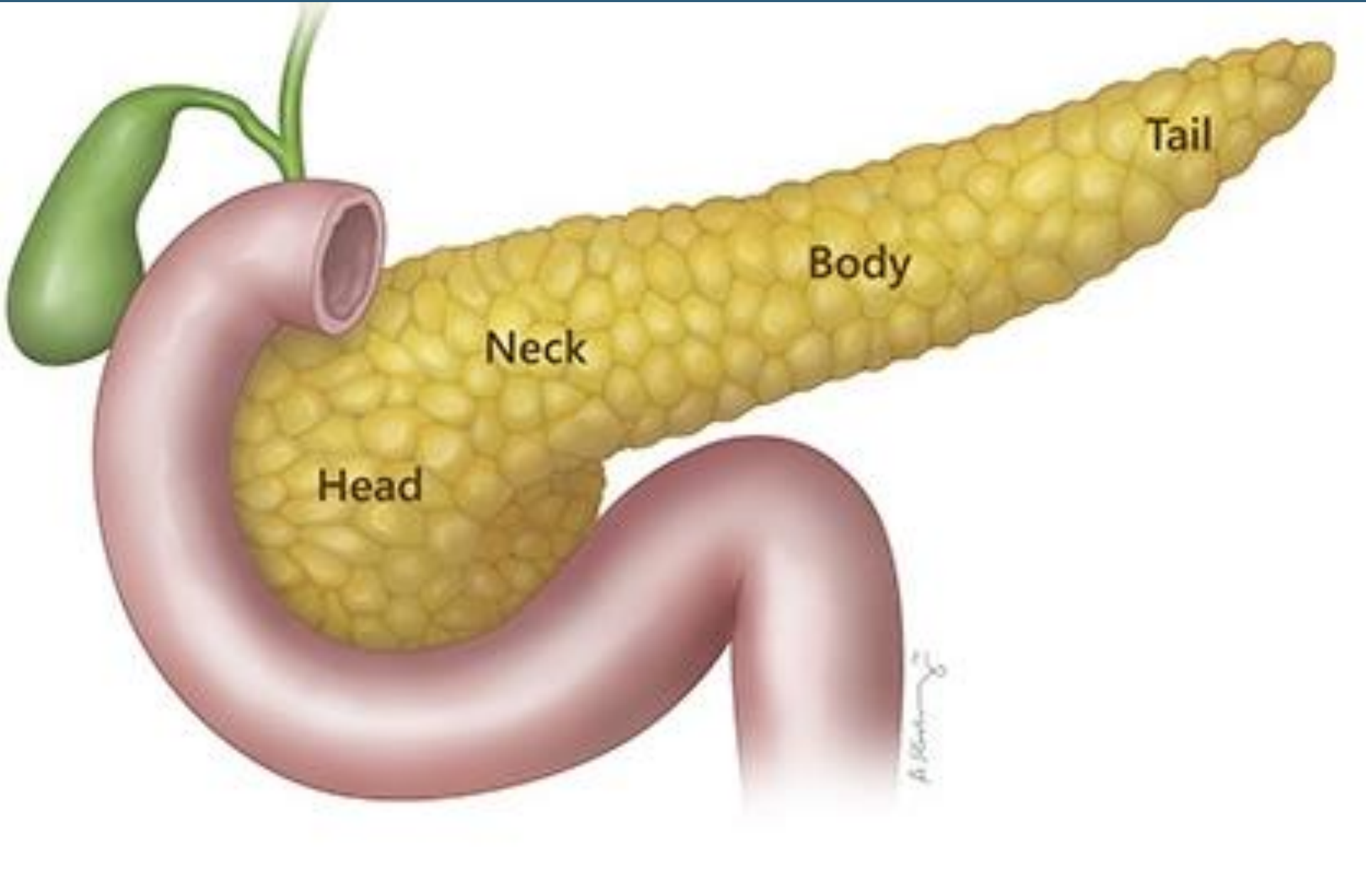
Intercostal Scan Plane





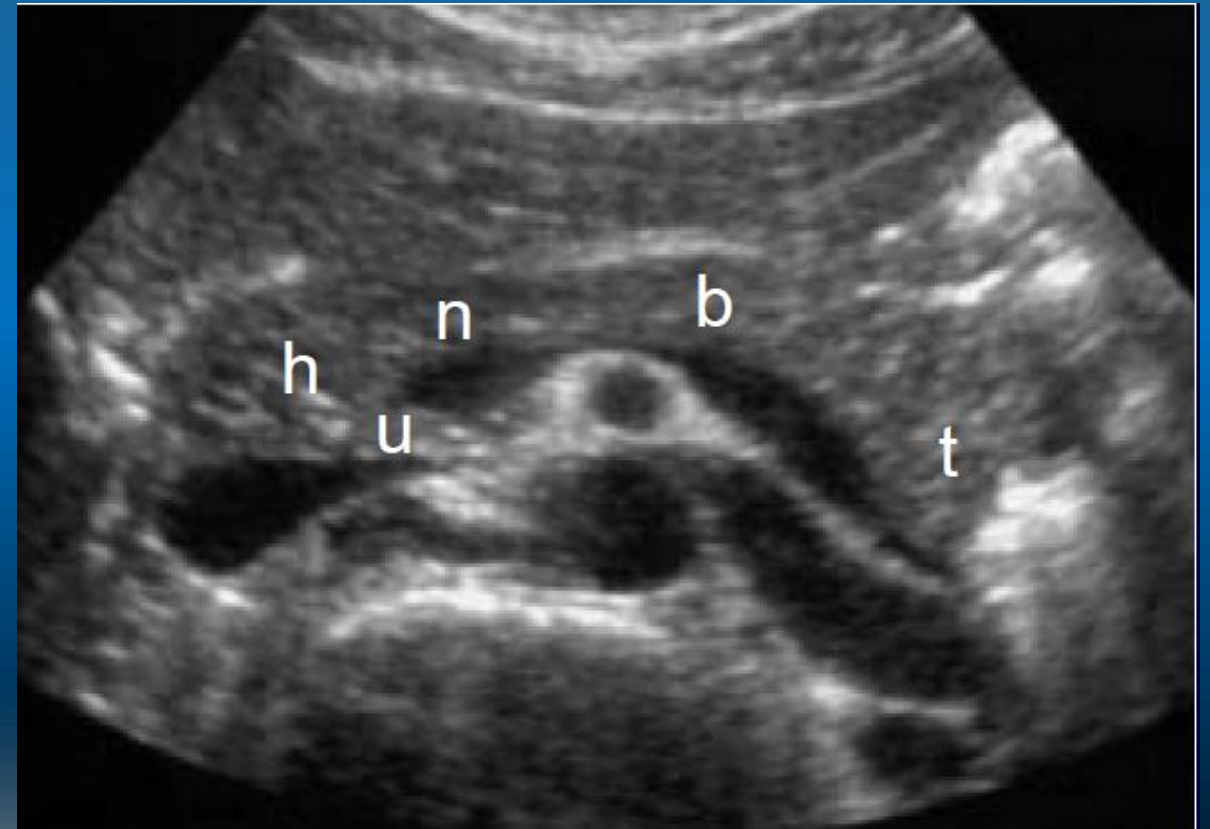
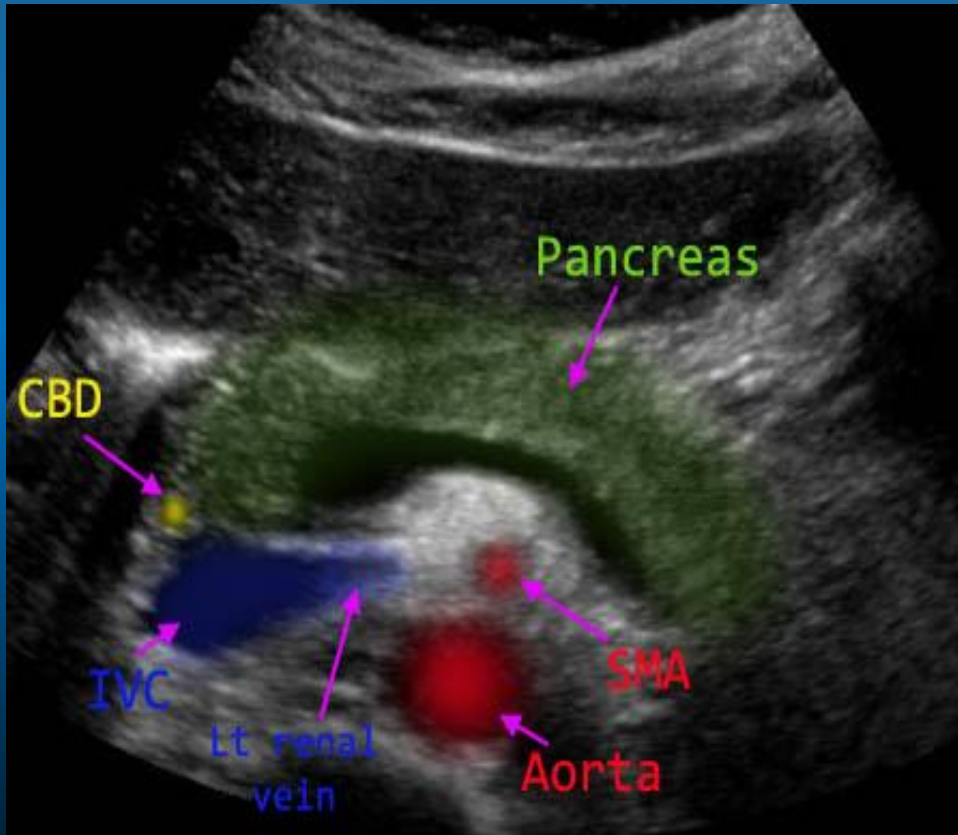
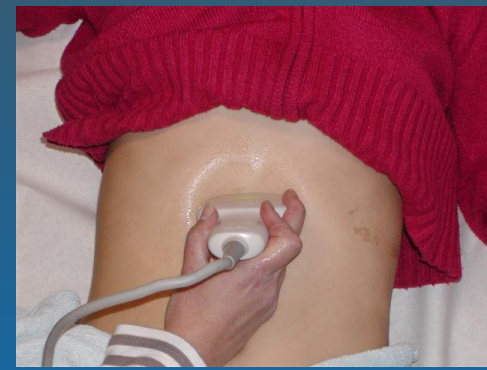© 2016 Columbia University. All Rights Reserved.

Adapt from <http://columbiasurgery.org/pancreas/pancreas-and-its-functions>



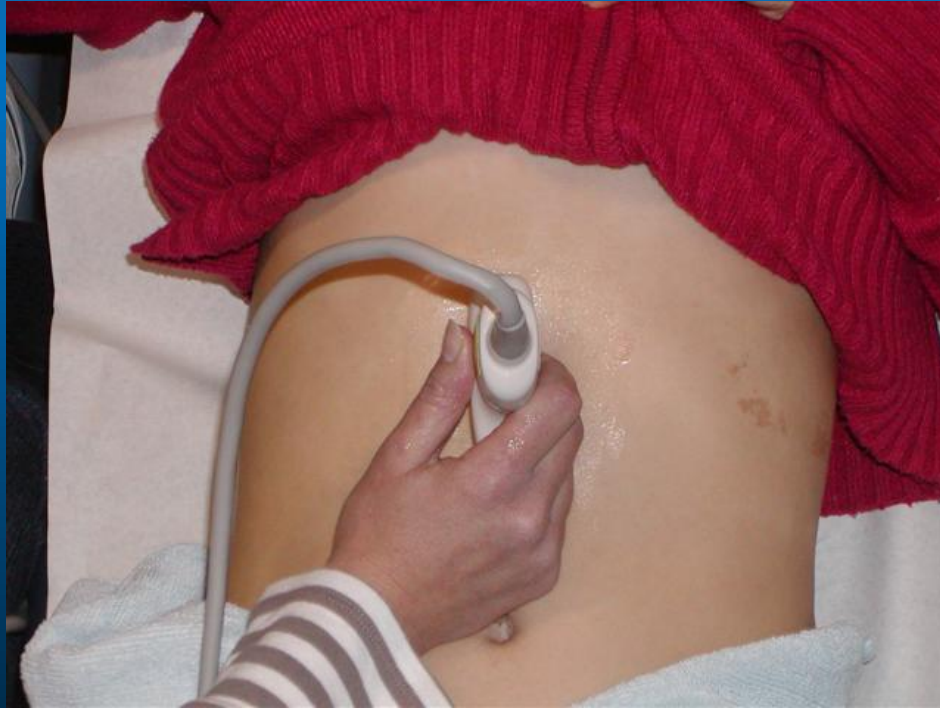Pancreas

Transverse View of the Pancreas

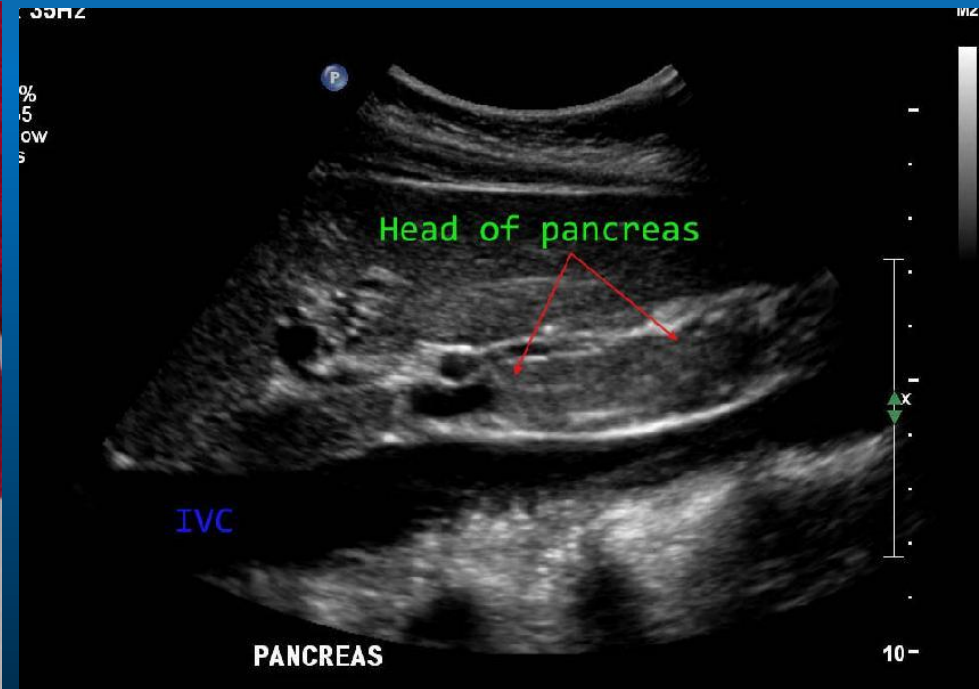


Pancreas

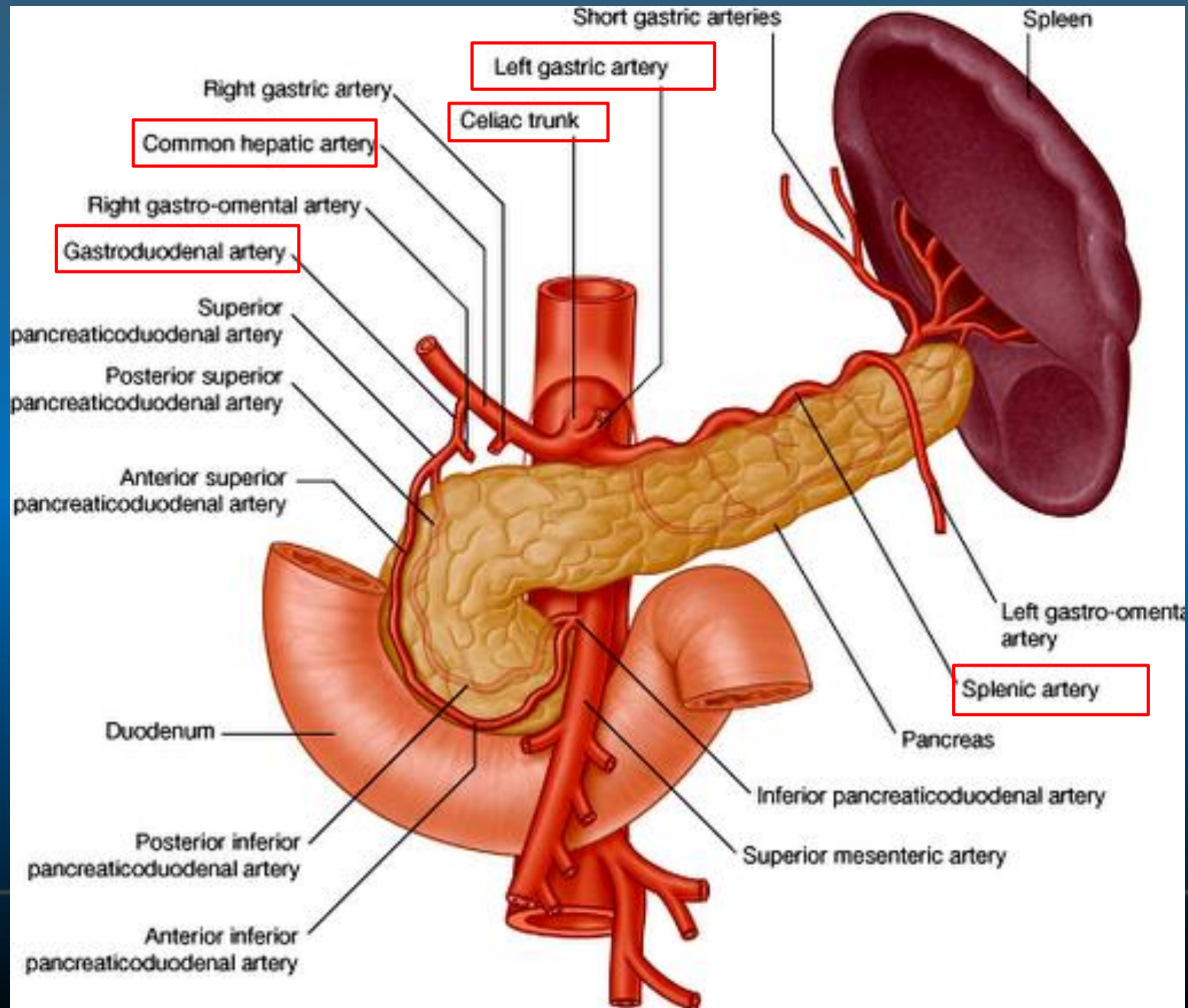
Sagittal View of the Pancreas



Sagittal Scan Plane Pancreatic Head



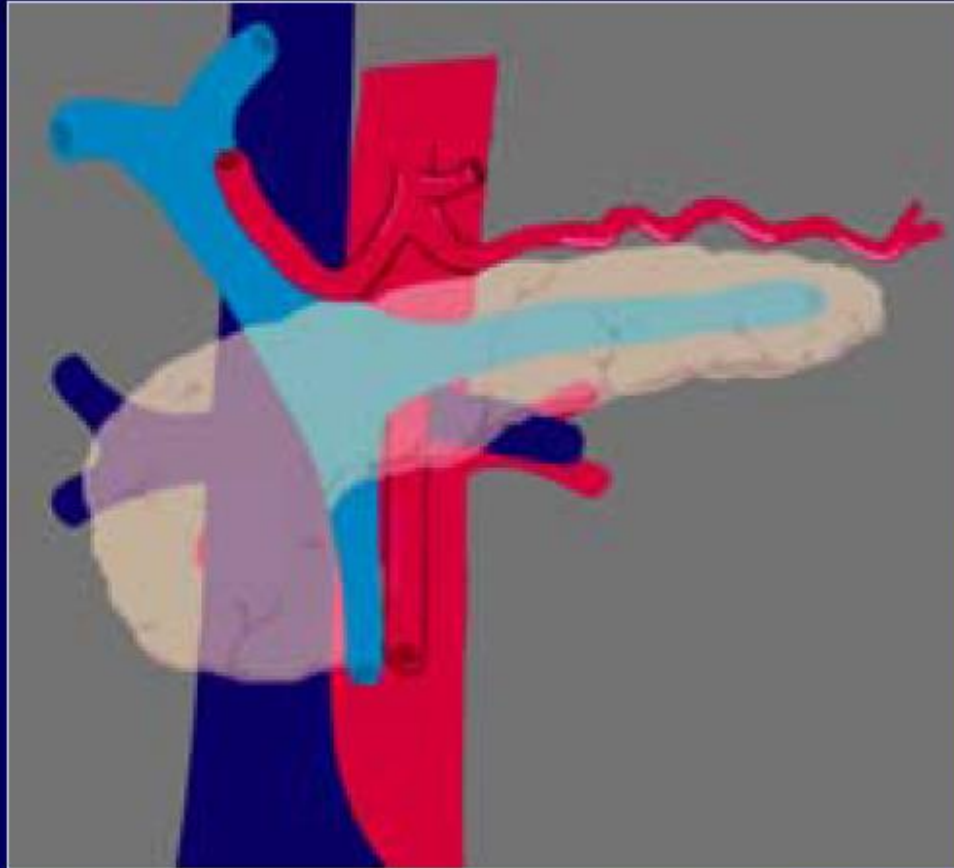Head of pancreas



Vascular Landmarks

■ Veins

- SV
- SMV
- MPV
- IVC

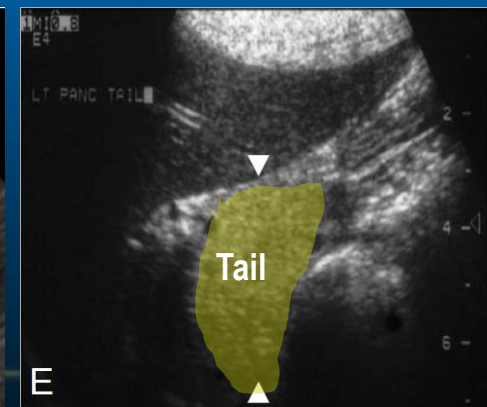
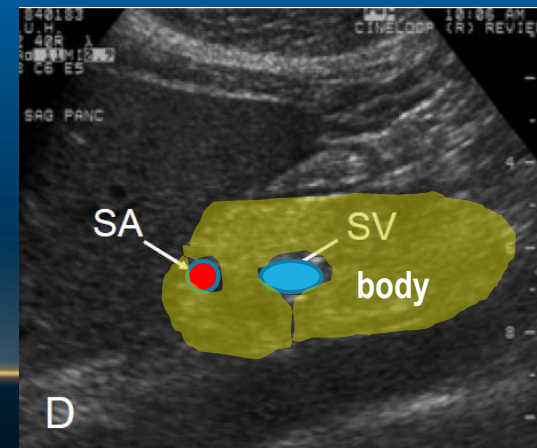
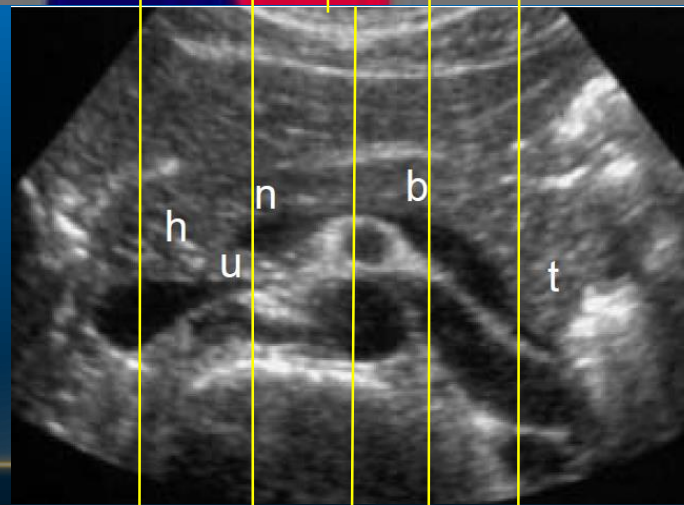
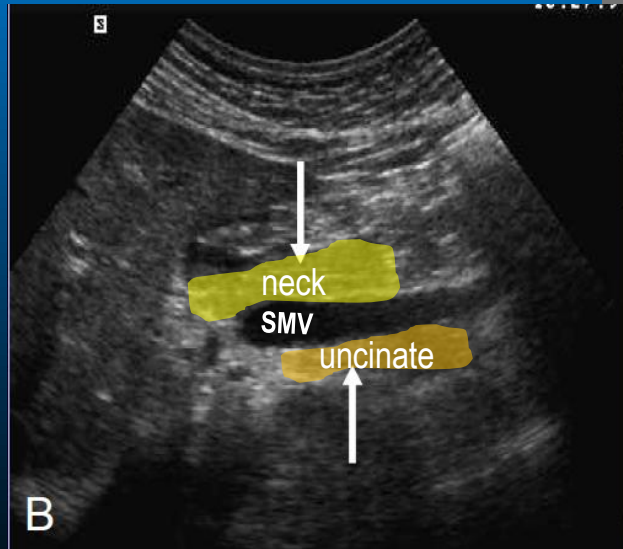
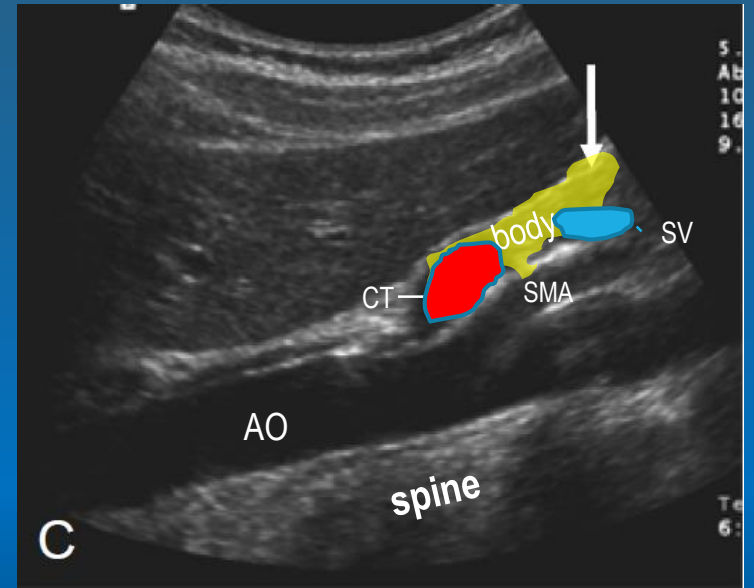

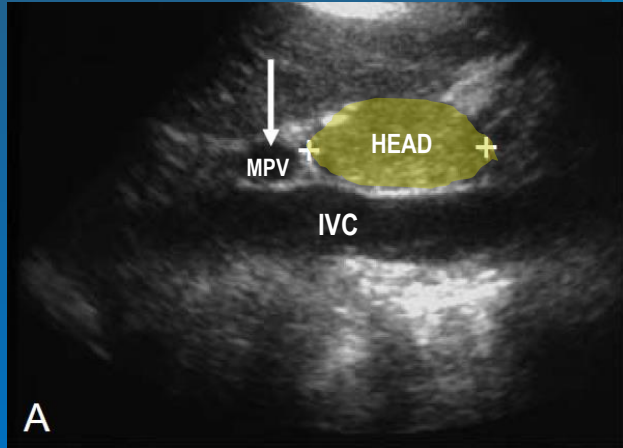


■ Arteries

- Aorta
- SMA
- Celiac
- Splenic
- GDA

Pancreas

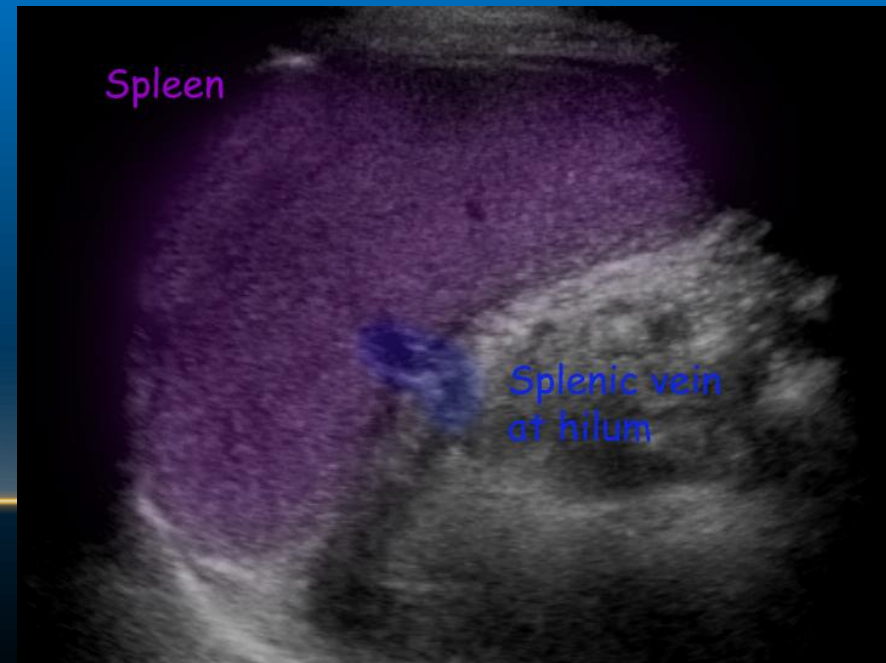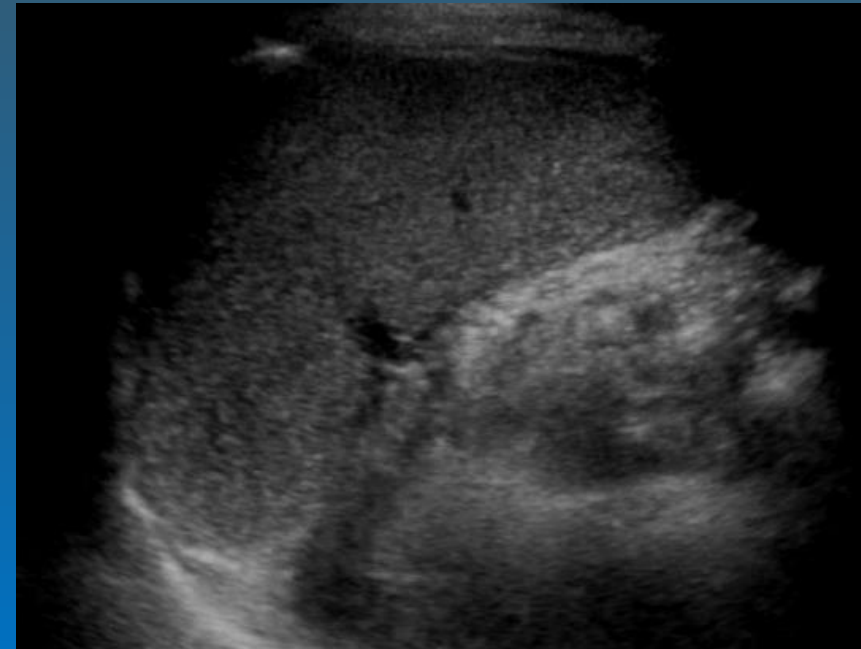
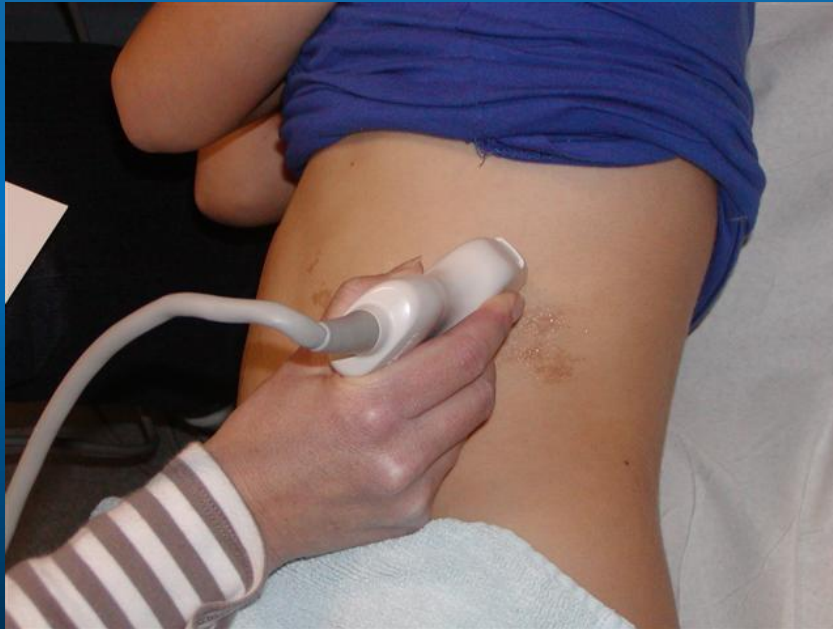Sagittal View of the Pancreas



A B C D E

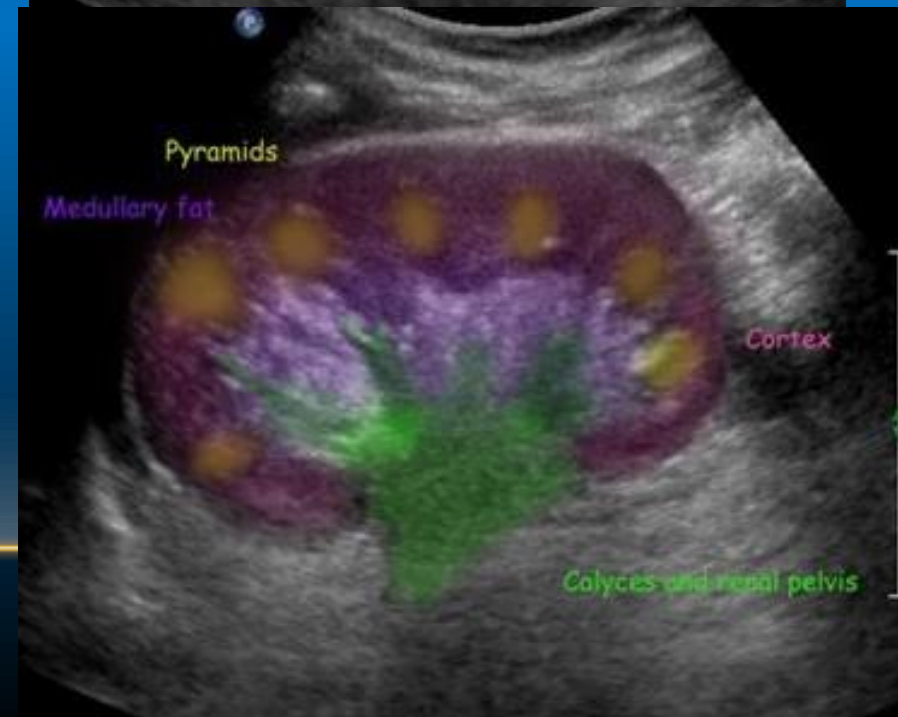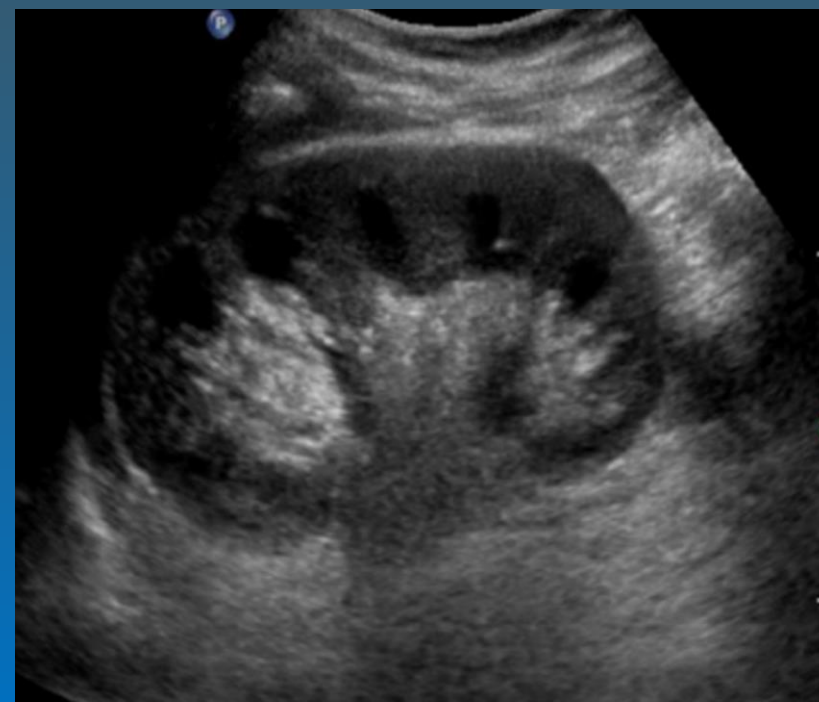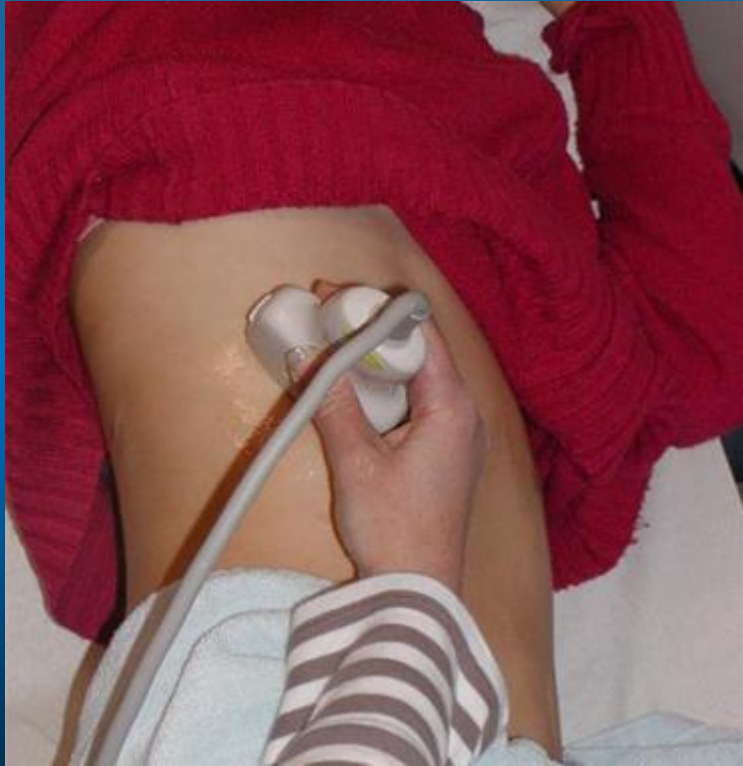SPLEEN

Intercostal scan plane



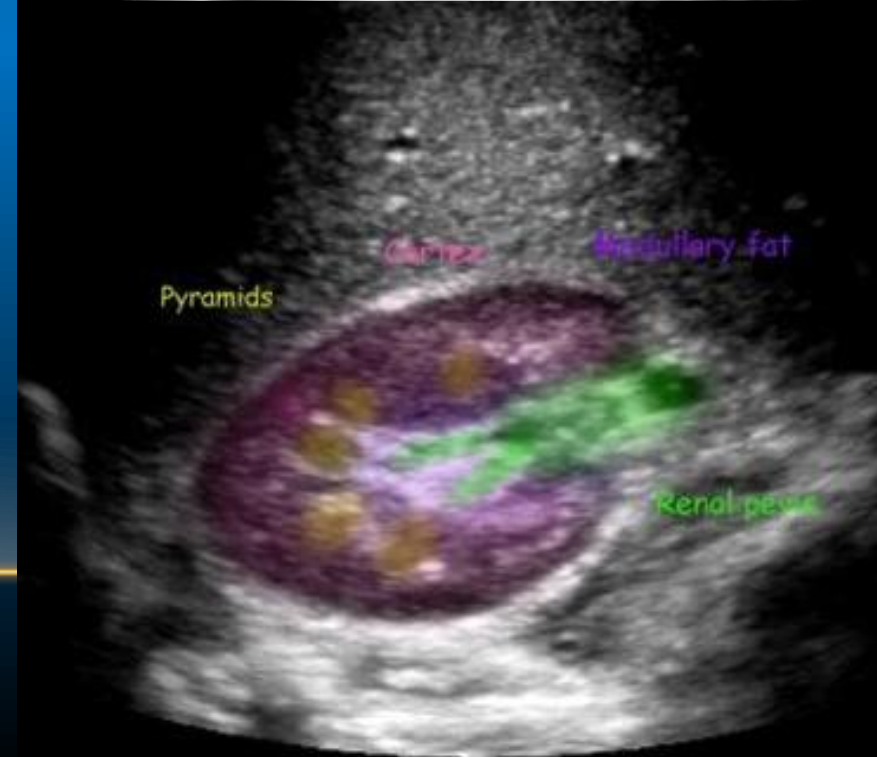
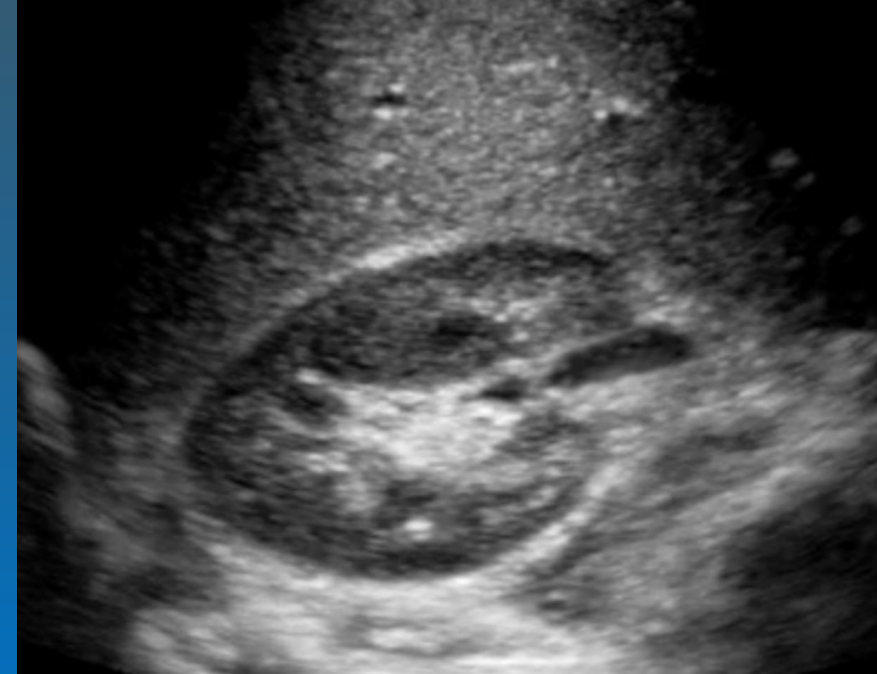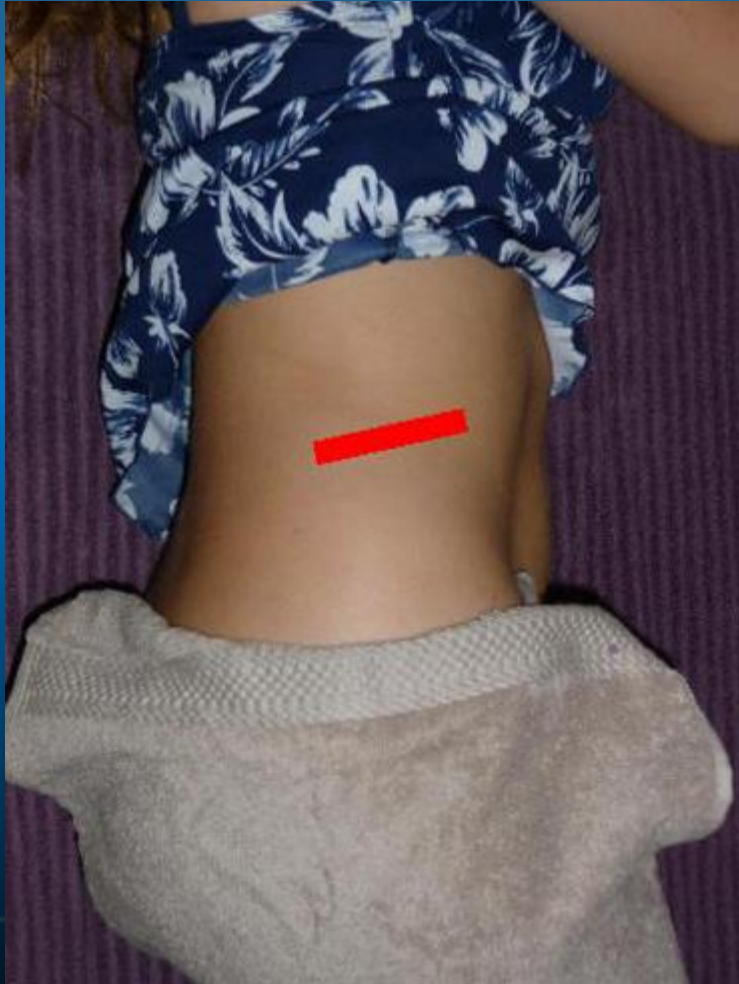Normal Spleen

Coronal scan plane for the Right Kidney



Longitudinal: Normal Kidney

Scan plane transverse kidney



E FAST

Subcostal	IVC	RUQ	LUQ	Pelvis (sagittal)	Schematic
					US Schematic
					US Image
Schematic	US Schematic	US Image			

			Pelvis (Transverse)
			Intercostal

eFAST Exam

Ultrasound Cheats

CRITICALCARE
NORTHAMPTON.COM
REVIEWING CRITICAL CARE, JOURNALS & FOAMED



Infographic by Dr. Jonny Wilkinson @Wilkinsonjonny

#ULTRASCOUNDREEL